

Hepatic venous pressure gradient in sinusoidal obstruction syndrome: diagnostic value and link with histological lesions

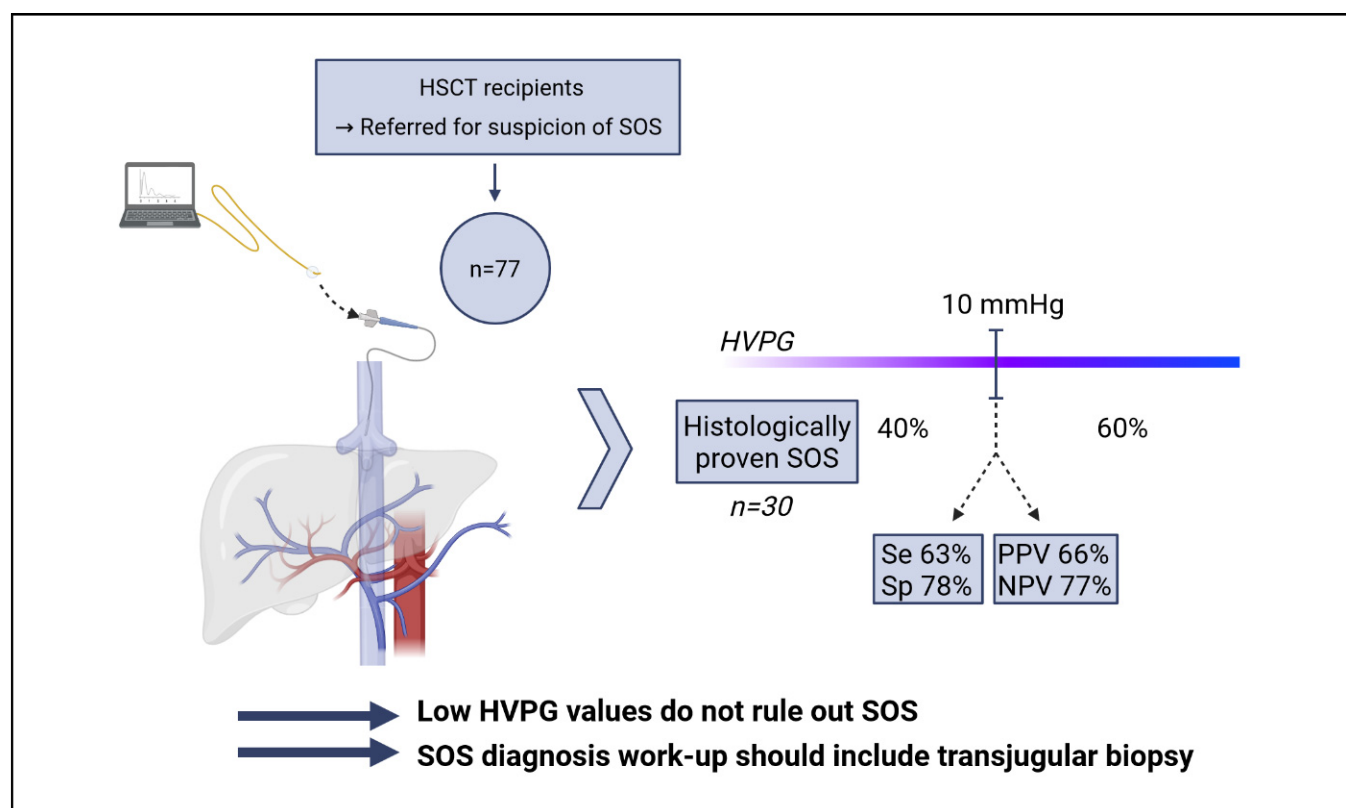
Authors

Simon B. Gressens, Dominique Cazals-Hatem, Virginie Lloyd, Aurélie Plessier, Audrey Payancé, Didier Lebre, François Durand, Gérard Socie, Dominique Valla, Valérie Paradis, David Michonneau, Pierre-Emmanuel Rautou

Correspondence

pierre-emmanuel.rautou@inserm.fr (P.-E. Rautou).

Graphical abstract



Highlights

- HVPG is significantly higher in patients with sinusoidal obstruction syndrome than in those with other liver injuries.
- A 10 mmHg threshold is associated with low PPV (66%) and low sensitivity (63%).
- HVPG measurement should be combined with transjugular liver biopsy when sinusoidal obstruction syndrome is suspected.

Lay summary

Hepatic venous pressure gradient >10 mmHg has been described as an accurate tool for the diagnosis of liver sinusoidal obstruction syndrome after hematopoietic stem cell transplantation. This study shows that the sensitivity and specificity of hepatic venous pressure gradient measurement for sinusoidal obstruction syndrome are insufficient, so that liver pressure measurement should be combined with a liver biopsy in this setting.



Hepatic venous pressure gradient in sinusoidal obstruction syndrome: diagnostic value and link with histological lesions

Simon B. Gressens,^{1,2} Dominique Cazals-Hatem,³ Virginie Lloyd,² Aurélie Plessier,^{1,2} Audrey Payancé,^{1,2} Didier Lebrec,^{1,2} François Durand,^{1,2} Gérard Socie,⁴ Dominique Valla,^{1,2} Valérie Paradis,³ David Michonneau,⁴ Pierre-Emmanuel Rautou^{1,2,*}

¹Université Paris-Cité, Inserm, Centre de recherche sur l'inflammation, UMR 1149, Paris, France; ²AP-HP, Service d'Hépatologie, Hôpital Beaujon, DMU DIGEST, Centre de Référence des Maladies Vasculaires du Foie, FILFOIE, ERN RARE-LIVER, Clichy, France; ³Service d'Anatomie pathologique, Hôpital Beaujon, Assistance Publique-Hôpitaux de Paris, Clichy, France; ⁴Service d'Hématologie Greffe, Hôpital Saint Louis, Assistance Publique Hôpitaux de Paris, Paris, France

JHEP Reports 2022. <https://doi.org/10.1016/j.jhepr.2022.100558>

Background & Aims: Liver sinusoidal obstruction syndrome (SOS) is a well-established complication of myeloablative conditioning regimens used in hematopoietic stem cell transplantation. Hepatic venous pressure gradient (HVPG) >10 mmHg was described as an accurate diagnostic tool for SOS in the 1990s. However, epidemiology and presentation of SOS have dramatically changed. Moreover, elementary histological lesions influencing HVPG are unknown.

Methods: We retrospectively analyzed the charts of all patients who underwent transjugular liver biopsy with HVPG measurement for a clinical suspicion of SOS at our center. Two expert pathologists unaware of the presence or absence of SOS reviewed all liver samples and graded elementary histological lesions according to a semi-quantitative scoring defined *a priori*.

Results: Out of the 77 included patients, the 30 patients with SOS had higher HVPG than the 47 patients without SOS (median 14 mmHg [IQR 10–18], vs. 6 mmHg [3–9], respectively $p < 0.001$). HVPG >10 mmHg had a specificity of 78% and a positive predictive value of 66% for the diagnosis of SOS. However, almost 40% of the patients with SOS had an HVPG ≤ 10 mmHg. HVPG correlated with sinusoidal congestion ($r = 0.57$; $p = 0.001$) and hepatocyte necrosis ($r = 0.42$; $p = 0.02$), but not with other lesions.

Conclusion: Even though HVPG is higher in patients with SOS, low HVPG values do not rule out SOS. Thus, HVPG cannot be used alone, and should be combined with transjugular liver biopsy, for the diagnosis of SOS.

Lay summary: Hepatic venous pressure gradient >10 mmHg has been described as an accurate tool for the diagnosis of liver sinusoidal obstruction syndrome after hematopoietic stem cell transplantation. This study shows that the sensitivity and specificity of hepatic venous pressure gradient measurement for sinusoidal obstruction syndrome are insufficient, so that liver pressure measurement should be combined with a liver biopsy in this setting.

© 2022 The Author(s). Published by Elsevier B.V. on behalf of European Association for the Study of the Liver (EASL). This is an open access article under the CC BY-NC-ND license (<http://creativecommons.org/licenses/by-nc-nd/4.0/>).

Introduction

Sinusoidal obstruction syndrome (SOS) is a well-established complication of myeloablative conditioning regimens used in hematopoietic stem cell transplantation (HSCT). SOS is caused by toxic injury to sinusoidal endothelial cells and characterized morphologically by a loss of sinusoidal wall integrity with consequent sinusoidal congestive obstruction, with or without occlusion of the centrilobular veins.¹

Signs regarded as suggestive of SOS include weight gain (fluid retention with or without ascites), tender hepatomegaly and jaundice, occurring classically in the first months after HSCT.^{1–3} However, SOS can occur later and these signs are not specific in the context of HSCT. Clinically, SOS ranges from the absence of

symptoms, to features of portal hypertension and severe multi-organ dysfunction, potentially leading to death. The European Association for the Study of the Liver Clinical Practice Guidelines on vascular diseases of the liver thus considered that diagnosing SOS following HSCT remains challenging.^{1,4} These guidelines, as well as the American Association for the Study of Liver Diseases Guidelines, suggest that a hepatic venous pressure gradient (HVPG) >10 mmHg can help identify patients with SOS.^{5–7} The New European Society for Blood and Marrow Transplantation criteria for SOS/veno-occlusive disease diagnosis in adults also takes hemodynamics into account. These statements are based on only three studies from the 1990s.^{6–8} However, the spectrum of SOS has changed since that period as its incidence following HSCT has decreased from 50% to 15% and conditioning regimens have changed, with an increased proportion of reduced-intensity conditioning regimens.^{9–11} Recent experimental studies have clarified the pathogenesis of the disease, shifting from a centrilobular vein involvement paradigm towards a model including hepatic sinusoid lesions as a pivotal mechanism.^{12,13} This change in SOS population over the last 25 years prompted us to revisit the diagnostic

Keywords: portal hypertension; liver biopsy; jaundice; ascites.

Received 29 April 2022; received in revised form 21 July 2022; accepted 28 July 2022; available online 17 August 2022

* Corresponding author. Address: Service d'Hépatologie, Hôpital Beaujon, Assistance Publique-Hôpitaux de Paris, Clichy, France; Tel.: +33 1 40 87 52 83, fax: + 33 1 40 87 55 30

E-mail address: pierre-emmanuel.rautou@inserm.fr (P.-E. Rautou).



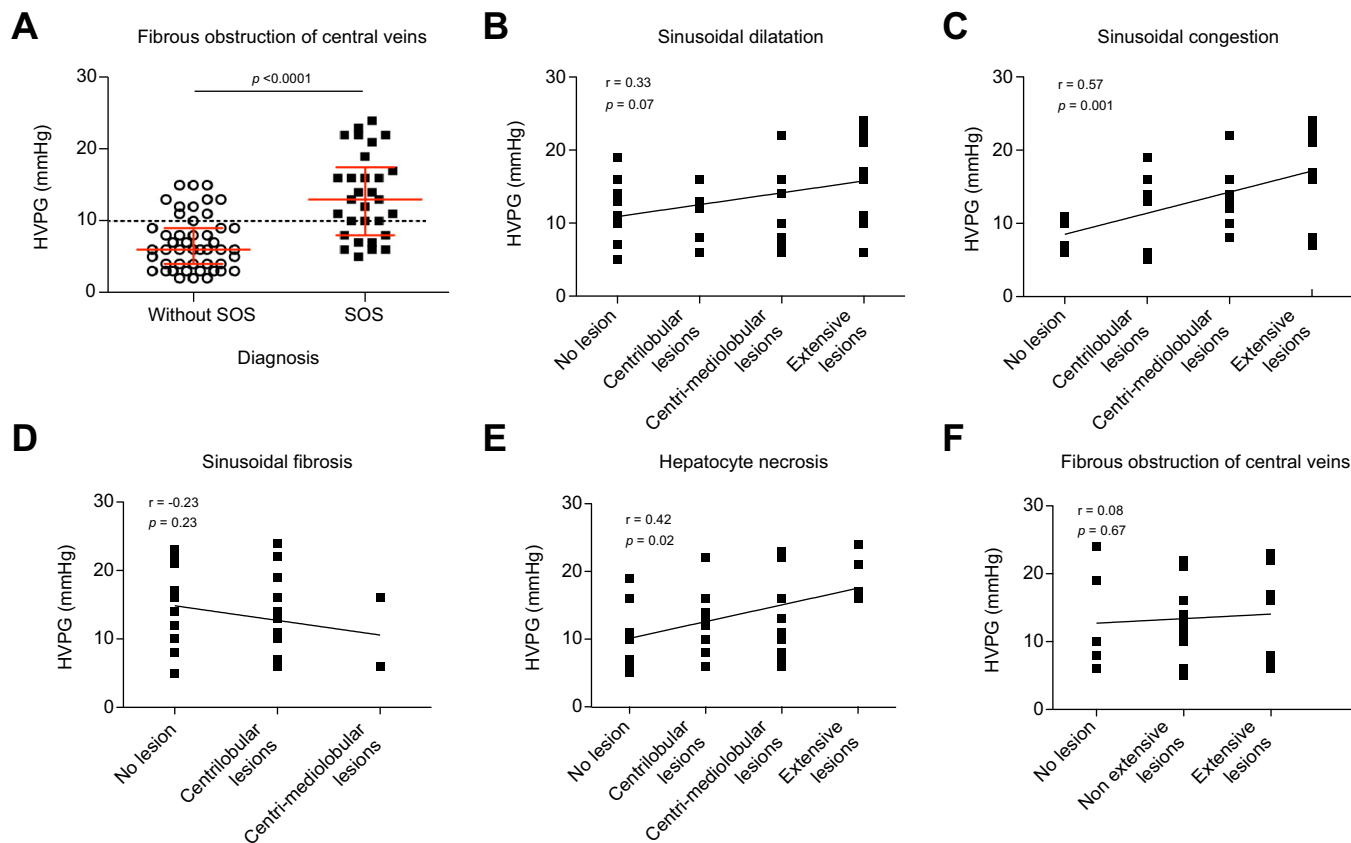


Fig. 1. HVPG in 77 patients with a clinical suspicion of SOS and correlation between HVPG and histological lesions in 30 patients with SOS. (A) Mann-Whitney test used. (B to F) Spearman test used. Black bars represent median and IQR. Histological lesions were graded according to a semi-quantitative scoring defined *a priori*: grade 0, no lesion; grade 1, non-extensive perivenular lesions limited to centrilobular sinusoids; grade 2, extensive lesions affecting centrilobular areas up to mediolobular sinusoids; grade 3, severe sinusoidal lesions extending to periportal zones. HVPG, hepatic venous pressure gradient; SOS, sinusoidal obstruction syndrome.

value of HVPG in SOS as well as to determine elementary histological features that influence HVPG.

Patients and methods

Patients

We retrospectively analyzed the charts of all the patients referred, between 1993 and August 2017, from hematology departments in the Paris area to our liver hemodynamic laboratory for transjugular liver biopsy and HVPG measurement due to a clinical suspicion of SOS. Suspicion of SOS was based on one or more of the following criteria, occurring within 6 months after HSCT: bilirubin $>34.2 \mu\text{mol/L}$, detectable ascites, suspicion of SOS by the hematologist in charge of the patient. We did not choose the Seattle or Baltimore criteria since these scores have an unclear sensitivity and specificity, as reviewed elsewhere.^{1,2} The protocol was performed in accordance with ethical guidelines of the 1975 Declaration of Helsinki and was approved by the institutional review board (CPP Sud Méditerranée, France).

Hemodynamic evaluation

Detailed methods for hemodynamic evaluation are provided in the supplementary methods. Wedge hepatic venous pressure was measured using straight catheters between 1993 and 2012, and balloon occlusion catheters from 2013.

Histological analysis

Detailed methods for histological analysis are provided in the supplementary methods and Fig. S1. Briefly, all liver samples were retrospectively reviewed by two expert pathologists (DCH and VP) unaware of the presence or absence of SOS.

As we included early- and late-onset SOS, SOS was defined as: (a) dilation and engorgement of sinusoids with extravasation of red cells, associated with various perivenular and/or central vein changes, including frank necrosis of perivenular hepatocytes, sinusoidal fibrosis as well as subendothelial edema and hemorrhage in the venule wall; or (b) fibrous obstruction of the central vein associated or not with other lesions. Intensity and extent of the lesions were assessed through gradation of the following histological features: sinusoidal dilatation, sinusoidal congestion, sinusoidal fibrosis, hepatocytes necrosis, fibrous obstruction of central veins.

Statistical analysis

Unless otherwise stated, quantitative variables were expressed as median (IQR) and categorical variables as frequencies. Comparisons of independent quantitative and qualitative variables between groups were performed using the Mann-Whitney test and the Chi-square or Fisher exact tests as appropriate, respectively. The diagnostic performance of HVPG $>10 \text{ mmHg}$, a threshold previously proposed,⁴ was assessed using sensitivity,

Table 1. Diagnostic performance of HVPG for the diagnosis of sinusoidal obstruction syndrome.

	Shulman ⁶	Carreras ^{7,8}	Kis ¹⁴	Present study
Total number of included patients	47	59	141	77
Number with SOS	23	17	44	30
HVPG in patients with SOS (mean ± SD mmHg)	13.5 ± 7.4	12.1 ± 5.7	16.2 ± 9.2	13.5 ± 5.7
Sensitivity of HVPG >10 mmHg	12/23 (52%)	11/18 (61%)-14/17 (82%) ¹	77% ²	19/30 (63%)
Specificity of HVPG >10 mmHg	22/24 (91%)	12/12 (100%)	91% ²	37/48 (78%)
PPV of HVPG >10 mmHg	12/14 (86%)	11/11 (100%)	76% ²	19/29 (66%)
NPV of HVPG ≤10 mmHg	22/33 (67%)	12/19 (63%)	92% ²	37/48 (77%)

HVPG, hepatic venous pressure gradient; NPV, negative predictive value; PPV, positive predictive value; SOS, sinusoidal obstruction syndrome.

¹ Carreras *et al.* studies with different sensitivities reported were combined here in the table.

² Absolute numbers were not available in the Kis *et al.* study.¹³

specificity, positive predictive value and negative predictive value. The relation between the HVPG and histological lesions of SOS was evaluated using Spearman Rho coefficient. All statistical tests were 2-sided. *P* values <0.05 were considered to be statistically significant. Statistical analyses were performed using the SPSS statistical package 16.0 software (SPSS Inc., Chicago, IL, United States) and GraphPad Prism 5 software, respectively.

Results

Characteristics of the patients

During the study period, 77 patients were referred to our hemodynamic laboratory for a clinical suspicion of SOS and included in the analysis (population characteristics available in Table S1). Patients included before 2012 had more pronounced liver blood test abnormalities, but the prevalence of SOS and HVPG values were similar between the two periods of time (Table S2).

Thirty patients had SOS confirmed at histological examination of liver biopsy. In the other 47 patients, the main histological diagnosis was graft vs. host disease (*n* = 26), inflammatory hepatitis (*n* = 4, including 1 viral hepatitis), hemophagocytic lymphohistiocytosis (*n* = 2), malignant hemopathic infiltration of the liver (*n* = 2), drug-induced steatosis (*n* = 2), non-alcoholic steatohepatitis (*n* = 1), spongiosis (*n* = 1) and non-contributive liver biopsy (*n* = 9).

Performance of HVPG for the diagnosis of SOS

Patients with SOS had a higher HVPG than those without. However, almost 40% of the patients with SOS had an HVPG ≤10 mmHg (Fig. 1). Therefore, the threshold of HVPG >10 mmHg had a specificity of 78% and a positive predictive value of 66% for the diagnosis of SOS (Table 1).

Of the 77 patients, the precise duration between HSCT and liver biopsy was available in 53 patients. Restricting the analyses to patients who had a liver biopsy within 3 months after HSCT (*n* = 47) gave similar results (specificity 78%, positive predictive value 67%). Restricting the analyses to patients suspected of having late-onset SOS (>21 days after HSCT (*n* = 40)) also gave similar results (specificity 81%, positive predictive value 62%). Considering HVPG ≥10 mmHg instead of >10 mmHg gave similar results as well (specificity 76%, positive predictive value 67%).

Features influencing HVPG in patients with SOS

We then investigated clinical, laboratory and histological features influencing HVPG in the 30 patients with histologically proven SOS.

As shown in Table S3, patients with SOS and HVPG >10 mmHg displayed more features of liver dysfunction than patients with HVPG ≤10 mmHg, as attested by higher serum bilirubin level (79 [29-277] vs. 30 [13-54]; *p* = 0.045) and lower prothrombin index (67.5 [53-85] vs. 88 [83-99]; *p* = 0.02). No other difference in clinical and laboratory features was found between the two groups. Duration between HSCT and liver biopsy was not associated with HVPG.

Regarding histological lesions, sinusoidal congestion (*r* = 0.57; *p* = 0.001) and hepatocyte necrosis (*r* = 0.42; *p* = 0.02) correlated with HVPG (Fig. 1B-F), while sinusoidal dilatation, sinusoidal fibrosis, sinusoidal obstruction did not. Nodular regenerative hyperplasia (observed in 3 patients), steatosis (observed in 4 patients) and bile deposits (observed in 10 patients) were not associated with HVPG (data not shown).

Discussion

Patients with a clinical suspicion of SOS following HSCT commonly have severe thrombocytopenia. Being minimally invasive, HVPG measurement has been proposed as a marker of SOS.⁵⁻⁷ Even though we found in the present study that patients with SOS have higher HVPG than those without, the diagnostic performance of HVPG alone is not high enough to replace liver biopsy.

The major finding of the present study is the observation that HVPG lacks sensitivity for the diagnosis of SOS. Comparison of our results with those from previous studies is presented in Table 1. Sensitivity of HVPG for the diagnosis of SOS was uniformly shown to be limited. For instance, almost 40% of the patients with SOS had HVPG ≤10 mmHg in the present study. Low HVPG values thus do not rule out SOS. The specificity of HVPG for the diagnosis of SOS has varied across studies, with older studies reporting high levels of specificity and high positive predictive values (Table 1).^{6-8,13,14} Although no definite explanation for this variation can be put forward, we can speculate that SOS was more severe in older studies than in ours, as conditioning regimens were more intensive at that time than currently.¹⁰ Comparison of disease severity is limited as liver blood tests were not reported in older studies. Still, our observation that patients with SOS and HVPG >10 mmHg have significantly more pronounced features of liver dysfunction and more intense sinusoidal congestion and hepatocyte necrosis than those with SOS and HVPG ≤10 mmHg is consistent with this view.

SOS has also been described following oxaliplatin chemotherapy regimens used for downstaging colorectal liver metastases.^{1,15} Since presentation of SOS related to oxaliplatin is different from that of SOS following HSCT, our results cannot be extrapolated to oxaliplatin-related SOS.

Our study bears limitations. First, as patients were referred to our liver hemodynamic laboratory only to perform transjugular liver biopsy with HVPG measurement, we did not have detailed information on HSCT conditioning regimens, nor on patients' outcome following the procedure, including the potential link between HVPG and response to defibrotide. Second, the retrospective nature of our study spanning over two decades might have introduced biases related to changes in conditioning regimens or HVPG measurement technique. Yet, comparison of the two periods of time, namely before and after 2012 – when we changed our HVPG measurement technique – did not reveal obvious differences in HVPG values nor in the prevalence of SOS. Changes in conditioning regimen over time might account for the differences in laboratory values observed between the two periods of time (Table S2). Third, non-invasive tests, including liver stiffness measurement, were not available in our patients.

In recent years, non-invasive methods have been proposed for prediction and early diagnosis of SOS.^{16–20} Future studies should determine strategies combining non-invasive tests with HVPG measurement and transjugular liver biopsy, to improve diagnosis of SOS.

In conclusion, even though HVPG is higher in patients with SOS, HVPG cannot be used alone as a diagnostic clue for SOS after HSCT, considering the results of our study and data available in the literature. Indeed, a non-negligible proportion of patients with SOS are not detected efficiently by this method, especially non-severe SOS. Therefore, HVPG measurement does not obviate the need for a transjugular liver biopsy in patients with a suspicion of SOS following HSCT. Recent reports on the safety of transjugular liver biopsy in patients who have undergone HSCT support this perspective.^{21,22}

Abbreviations

HSCT, hematopoietic stem cell transplantation; HVPG, hepatic venous pressure gradient; NPV, negative predictive value; PPV, positive predictive value; SOS, sinusoidal obstruction syndrome.

Financial support

The authors received no financial support to produce this manuscript.

Conflicts of interest

The authors declare no competing financial interest.

Please refer to the accompanying ICMJE disclosure forms for further details.

Authors' contributions

S.B. Gressens: formal analysis, investigation, data curation, writing – original draft, visualization. D. Cazals-Hatem and V. Paradis: formal analysis, methodology, investigation, writing – review and editing, supervision. V. Lloy, A. Plessier, A. Payancé, D. Lebrec, F. Durand, G. Socie, D. Michonneau: investigation, resources, writing – review and editing. D. Valla: investigation, project administration, writing – review and editing. PE Rautou: conceptualization, investigation, resources, supervision, writing – review and editing, project administration.

Data availability statement

All data is available upon request to the corresponding author, as it includes patient data, therefore precluding uploading it on a widely accessible platform.

Acknowledgements

We thank Lucile Dehecq, Cécilia de Freitas, Anissa Messaïli, Maryse Moinat for their help in collecting the data. The Graphical abstract was created with BioRender.com.

Supplementary data

Supplementary data to this article can be found online at <https://doi.org/10.1016/j.jhepr.2022.100558>.

References

Author names in bold designate shared co-first authorship

- [1] European Association for the Study of the Liver. *EASL Clinical Practice Guidelines: vascular diseases of the liver*. *J Hepatol* 2016;64(1):179–202.
- [2] DeLeve LD, Valla DC, Garcia-Tsao G, American Association for the Study of Liver D. *Vascular disorders of the liver*. *Hepatology* 2009;49(5):1729–1764.
- [3] **Mohty M, Malard F, Abecassis M, Aerts E, Alaskar AS, Aljurf M**, et al. Revised diagnosis and severity criteria for sinusoidal obstruction syndrome/veno-occlusive disease in adult patients: a new classification from the European Society for Blood and Marrow Transplantation. *Bone Marrow Transpl* 2016;51:906–912.
- [4] Shulman HM, Fisher LB, Schoch HG, Henne KW, McDonald GB, et al. *Venoocclusive disease of the liver after marrow transplantation: histological correlates of clinical signs and symptoms*. *Hepatology* 1994;19(5):1171–1181.
- [5] Northup PG, Garcia-Pagan JC, Garcia-Tsao G, Itagliata NM, Superina RA, Roberts LN, et al. *Vascular liver disorders, portal vein thrombosis, and procedural bleeding in patients with liver disease: 2020 practice guidance by the American Association for the Study of Liver Diseases*. *Hepatology* 2021;73(1):366–413.
- [6] Schulman HGT, Dudley D, Kofler T, Feldman R, Dwyer D, McDonald G. *Utility of transvenous liver biopsies and wedged hepatic venous pressure measurements in sixty marrow transplant recipients*. *Transplantation* 1995;59(7):1015–1022.
- [7] Carreras E, Grañena A, Navasa M, Brugera M, Marco V, Sierra J, et al. *Transjugular liver biopsy in BMT*. *Bone Marrow Transpl* 1993;11(1):21–26.
- [8] Carreras E, Grañena A, Navasa M, Brugera M, Marco V, Sierra J, et al. *On the reliability of clinical criteria for the diagnosis of hepatic veno-occlusive disease*. *Ann Hematol* 1993;66(2):77–80.
- [9] McDonald GB, Slattery JT, Bouvier ME, Ren S, Batchelder AL, Kalthorn TF, et al. *Cyclophosphamide metabolism, liver toxicity, and mortality following hematopoietic stem cell transplantation*. *Blood* 2003;101(5):2043–2048.
- [10] **Coppell JA, Richardson PG**, Soiffer R, Martin PL, Kernan NA, Chen A, et al. *Hepatic veno-occlusive disease following stem cell transplantation: incidence, clinical course, and outcome*. *Biol Blood Marrow Transpl* 2010;16(2):157–168.
- [11] Gyurkocza B, Sandmaier BM. *Conditioning regimens for hematopoietic cell transplantation: one size does not fit all*. *Blood* 2014;124(3):344–353.
- [12] Rubbia-Brandt L. *Sinusoidal obstruction syndrome*. *Clin Liver Dis* 2010;14(4):651–668.
- [13] Vion AC, Rautou PE, Durand F, Boulanger CM, Valla DC. *Interplay of inflammation and endothelial dysfunction in bone marrow transplantation: focus on hepatic veno-occlusive disease*. *Semin Thromb Hemost* 2015;41(6):629–643.
- [14] Kis B, Pamarthi V, Fan C-M, Rabkin D, Baum RA. *Safety and utility of transjugular liver biopsy in hematopoietic stem cell transplant recipients*. *J Vasc Interv Radiol* 2013;24(1):85–89.
- [15] Ravaioli F, Colecchia A, Alemanni LV, Vestito A, Dajti E, Marasco G, et al. *Role of imaging techniques in liver veno-occlusive disease diagnosis: recent advances and literature review*. *Expert Rev Gastroenterol Hepatol* 2019;1–22.
- [16] Chan S, Colecchia A, Duarte R, Bonifazi F, Ravaioli F, Bourhis JH. *Imaging in hepatic veno-occlusive disease/sinusoidal obstruction syndrome*. *Biol Blood Marrow Transpl* 2020;20(10):1770–1779.
- [17] Bonifazi F, Barbato F, Ravaioli F, Sessa M, Defrancesco I, Arpinati M, et al. *Diagnosis and treatment of VOD/SOS after allogeneic hematopoietic stem cell transplantation*. *Front Immunol* 2020;11:489.
- [18] **Debureaux PE, Bourrier P**, Rautou PE, Zagdanski AM, De Boutiny M, Pagliuca S, et al. *Elastography improves accuracy of early hepato-biliary complications diagnosis after allogeneic stem cell transplantation*. *Hematologica* 2021;106(9):2374–2383.

- [19] **Colecchia A, Ravaioli F, Sessa M, Alemanni VL, Dajti E, Marasco G, et al.** Liver stiffness measurement allows early diagnosis of veno-occlusive disease/sinusoidal obstruction syndrome in adult patients who undergo hematopoietic stem cell transplantation: results from a monocentric prospective study. *Biol Blood Marrow Transplant* 2019;25(5):995–1003.
- [20] Colecchia A, Marasco G, Ravaioli F, Kleinschmidt K, Masetti R, Prete A, et al. Usefulness of liver stiffness measurement in predicting hepatic veno-occlusive disease development in patients who undergo HSCT. *Bone Marrow Transplant* 2017;52(3):494–497.
- [21] Valla D-C, Cazals-Hatem D. Sinusoidal obstruction syndrome. *Clin Res Hepatol Gastroenterol* 2016;40(4):378–385.
- [22] Ahmed O, Ward TJ, Lungren MP, Abdelrazek Mohammed MA, Hofmann LV, Sze DY, et al. Assessing the risk of hemorrhagic complication following transjugular liver biopsy in bone marrow transplantation recipients. *J Vasc Interv Radiol* 2016;27(4):551–557.