



Portal vein thrombosis: diagnosis, management, and endpoints for future clinical studies

Laure Elkrief, Virginia Hernandez-Gea, Marco Senzolo, Agustin Albillos, Anna Baiges, Annalisa Berzigotti, Christophe Bureau, Sarwa Darwish Murad, Andrea De Gottardi, François Durand, Juan-Carlos Garcia-Pagan, Ton Lisman, Mattias Mandorfer, Valérie McLin, Lucile Moga, Filipe Nery, Patrick Northup, Alexandre Nuzzo, Valérie Paradis, David Patch, Audrey Payancé, Vincent Plaforet, Aurélie Plessier, Johanne Poisson, Lara Roberts, Riad Salem, Shiv Sarin, Akash Shukla, Christian Toso, Dhiraj Tripathi, Dominique Valla, Maxime Ronot, Pierre-Emmanuel Rautou, on behalf of ERN RARE-LIVER and VALDIG, an EASL consortium

Portal vein thrombosis (PVT) refers to the development of a non-malignant obstruction of the portal vein, its branches, its radicles, or a combination. This Review first provides a comprehensive overview of all aspects of PVT, namely the specifics of the portal venous system, the risk factors for PVT, the pathophysiology of portal hypertension in PVT, the interest in non-invasive tests, as well as therapeutic approaches including the effect of treating risk factors for PVT or cause of cirrhosis, anticoagulation, portal vein recanalisation by interventional radiology, and prevention and management of variceal bleeding in patients with PVT. Specific issues are also addressed including portal cholangiopathy, mesenteric ischaemia and intestinal necrosis, quality of life, fertility, contraception and pregnancy, and PVT in children. This Review will then present endpoints for future clinical studies in PVT, both in patients with and without cirrhosis, agreed by a large panel of experts through a Delphi consensus process. These endpoints include classification of portal vein thrombus extension, classification of PVT evolution, timing of assessment of PVT, and global endpoints for studies on PVT including clinical outcomes. These endpoints will help homogenise studies on PVT and thus facilitate reporting, comparison between studies, and validation of future studies and trials on PVT.

Introduction

The term portal vein thrombosis (PVT) refers to the development of a non-malignant obstruction in the portal vein, its branches, its radicles, or a combination. Tumorous occlusion of the portal vein—erroneously referred to as malignant thrombosis—is characterised by the intraluminal development of malignant tissue and will not be discussed here. PVT can develop in patients without underlying liver disease or affect patients with chronic liver disease, mostly those with cirrhosis and more rarely porto-sinusoidal vascular disorder or Budd-Chiari syndrome.

Recent PVT refers to the formation of a thrombus in the portal vein, its branches, its radicles, or a combination within the last 6 months. Ultrasound coupled with Doppler is usually the first-line diagnostic method, allowing the direct detection of the thrombus in the portal vein and the absence of flow in case of complete PVT. Contrast-enhanced CT is usually preferred to MRI to support the diagnosis of PVT, and is likely to show a hyperattenuating (hyperintense) thrombus on the unenhanced phase and an absence of enhancement of the lumen in the contrast-enhanced portal venous phase. Enlargement of the portal vein can be observed when PVT is complete and recent.¹ Chronic PVT refers to either portal cavernoma or incomplete resolution of the portal vein obstruction 6 months after a recent PVT. Diagnosis of chronic PVT is based on contrast-enhanced CT or MRI. Typical features include an absence of visualisation of the portal vein, usually associated with a cavernoma (ie, tortuous porto-portal collaterals bypassing the occluded portion of the portal vein), enhancing after contrast injection.² This imaging also allows congenital malformation of the portal vein, such as congenital

absence of the portal vein (also known as Abernethy malformation), to be excluded. When performed by experienced radiologists, reported accuracy for the diagnosis of PVT at imaging ranges from 88–98% and with sensitivity and specificity values of 80–100%.³ Diagnostic accuracy might be lower when the radiologist is not aware of the suspicion of PVT, or when the quality of the images are suboptimal.⁴

In patients without cirrhosis, complete obstruction of the main portal vein, or obstruction of both of its two branches, is the predominant form (>80% of the patients).⁵ Conversely, in patients with cirrhosis, non-occlusive PVT (ie, when the lumen is only partially occluded by the thrombus) accounts for around 70% of the cases.⁶ PVT, in the absence of cirrhosis, is a rare disease. However, collaborative efforts conducted over the last two decades have yielded new knowledge on PVT pathophysiology and management. PVT developing in patients with cirrhosis is much more common and has also been the subject of numerous recent studies.

Methods

VALDIG (Vascular Liver Disease Group) is an independent network of researchers with a common interest in vascular liver diseases endorsed by the European Association for the Study of the Liver (EASL) that aims to foster research in this field. In November, 2022, the VALDIG steering committee held an International Expert Conference on PVT in Paris, France, and included a faculty of 35 international experts.

The first part of this Review consists of an extensive review of the current knowledge on PVT, summarising the lectures given during the meeting. Faculty members

Lancet Gastroenterol Hepatol 2024

Published Online
July 9, 2024
[https://doi.org/10.1016/S2468-1253\(24\)00155-9](https://doi.org/10.1016/S2468-1253(24)00155-9)

Investigators listed in the appendix (p 1)

Faculté de médecine de Tours, et service d'hépatogastroentérologie, Le Centre Hospitalier Régional Universitaire de Tours, Tours, France (Prof L Elkrief); Centre de recherche sur l'inflammation, Université Paris-Cité, Paris, France (Prof L Elkrief, Prof F Durand, L Moga, A Payancé, A Plessier, J Poisson, Prof D Valla, Prof M Ronot, Prof P-E Rautou); Barcelona Hepatic Hemodynamic Laboratory, Liver Unit, Hospital Clínic de Barcelona, Institut de Investigacions Biomèdiques August Pi i Sunyer, Barcelona, Spain (V Hernandez-Gea, A Baiges, J-C Garcia-Pagan); Centro de Investigación Biomédica en Red Enfermedades Hepáticas y Digestivas, Madrid, Spain (V Hernandez-Gea, A Baiges, J-C Garcia-Pagan, Prof A Albillos); Departament de Medicina i Ciències de la Salut, Universitat de Barcelona, Barcelona, Spain (V Hernandez-Gea, A Baiges, J-C Garcia-Pagan); Department of Surgery, Oncology and Gastroenterology, University of Padova, Padova, Italy (M Senzolo); Departamento de Gastroenterología y Hepatología, Instituto Ramón y Cajal de Investigación Sanitaria, Hospital Universitario Ramon y Cajal, Madrid, Spain (Prof A Albillos); Department of Visceral Surgery and Medicine, Inselspital, Bern University Hospital, Bern, Switzerland (Prof A Berzigotti); Service d'Hépatologie Hôpital Rangueil, Université Paul Sabatier, Toulouse, France (Prof C Bureau); Department of Gastroenterology and

Hepatology, Erasmus MC University Medical Center, Rotterdam, Netherlands (S D Murad); Gastroenterology and Hepatology Department, Ente Ospedaliero Cantonale Faculty of Biomedical Sciences of Università della Svizzera Italiana, Lugano, Switzerland (Prof A De Gottardi); Service d'Hépatologie (Prof F Durand, L Moga, A Payancé, A Plessier, Prof D Valla, Prof P-E Rautou), Department of Pathology (Prof V Paradis), and Service de Radiologie (V Plaforet, Prof M Ronot), AP-HP Hôpital Beaujon, Clichy, France; Department of Surgery, University Medical Center Groningen, Groningen, Netherlands (Prof T Lisman); Vienna Hepatic Hemodynamic Lab, Division of Gastroenterology and Hepatology, Department of Medicine III, Medical University of Vienna, Vienna, Austria (M Mandorfer); Swiss Pediatric Liver Center, Department of Pediatrics, Gynecology and Obstetrics, University of Geneva, Geneva, Switzerland (Prof V McLin); Immunology and Pharmacology Department, School of Medicine and Biomedical Sciences, University of Porto, Portugal (F Nery); Transplant Institute and Division of Gastroenterology, NYU Langone, New York, NY, USA (Prof P Northup); Intestinal Stroke Center, Department of Gastroenterology, IBD and Intestinal Failure, AP-HP Hôpital Beaujon, Clichy, France (A Nuzzo); Laboratory for Vascular and Translational Science, INSERM UMR 1148, Paris, France (A Nuzzo); Department of Hepatology and Liver Transplantation, Royal Free Hospital, London, UK (Prof D Patch); Service de Gériatrie, Hôpital Corentin Celton (AP-HP), Paris, France (J Poisson); Department of Haematological Medicine, King's College Hospital NHS Foundation Trust, London, UK (L Roberts); Northwestern Memorial Hospital, Northwestern University, Chicago, IL, USA (Prof R Salem); Institute of Liver and Biliary Sciences, New Delhi, India (Prof S Sarin); Department of Gastroenterology, Seth GS Medical College and KEM Hospital, Mumbai, India

of the Paris PVT meeting wrote a section of this review and reviewed the whole manuscript.

The second part of the Review is dedicated to endpoints for future clinical studies on PVT. These endpoints are the result of extensive discussions that took place in 2022 and 2023 during and after the Paris PVT meeting. These endpoints were proposed by the organisers of the conference to a panel of 57 experts and were voted on in January, 2024, according to a Delphi method (appendix p 31–34).

The specifics of the portal venous system Characteristics of the portal vein

From an embryological point of view, the portal venous system develops from the vitelline venous system.⁷ Since adult blood cells also derive from the vitelline venous system,⁸ this might explain the strong association between myeloproliferative neoplasms and splanchnic vein thrombosis, although evidence to support this hypothesis is absent.

Physiologically, the portal venous system has some specific characteristics: it does not drain into the heart; it does not have venous valves; it drains capillaries from the abdominal organs and thereafter ramifies into an extensive network of liver sinusoids; and it is a low-pressure system. The portal venous system is a high-compliance, low-resistance system that can accommodate a large blood volume, as occurs after a meal, without substantially increasing portal pressure. Histologically, the portal vein wall is composed of tunica intima with endothelial cells and subendothelial connective tissue. It contains scattered fibroblasts and is bounded externally by a network of elastic fibres, similar to veins from the systemic venous system. Specifics of the phenotype of endothelial cells lining the portal venous system, especially the extrahepatic system where PVT usually occurs, are not entirely known. Several single-cell transcriptomic analyses performed in healthy individuals showed that portal endothelial cells have a distinct phenotype from other liver endothelial cells,^{9–12} but a comparison with other vascular beds has not been performed. Performing such comparisons might uncover mechanisms explaining the pathogenesis of PVT.

In cirrhosis, the portal venous system has modifications due to the increase in portal venous pressure (portal hypertension): the calibre of the portal venous system increases to accommodate the increase in portal venous flow and the thickness of the vein increases due to hypertrophy of its walls, particularly in the intima layer.¹³ Indeed, data from preclinical models, both in vitro and in vivo, revealed that pressure-induced mechanical stress causes an increase in the size and the number of smooth muscle cells, leading to a thickening of the vessel wall.^{14,15} Patients with cirrhosis and severe portal hypertension requiring liver transplant have a variable degree of intimal thickening affecting the portal vein wall focally or circumferentially with an increase in the number of

fibroblasts (figure 1). These changes are more pronounced in patients with cirrhosis and PVT than in those without.¹⁶ Understanding why these changes occur and their contribution to portal vein thrombosis is an attractive field that requires further research.

Haemostasis in the portal circulation

In patients with cirrhosis, there are well-documented changes in the haemostatic system in the systemic circulation. These include thrombocytopenia and decreased plasma levels of coagulation factors, inhibitors of coagulation, and proteins involved in clot breakdown.¹⁷ The net result of all haemostatic alterations is a haemostatic system that seems to be in fragile balance, with both hypocoagulable and hypercoagulable features. Different groups have investigated haemostatic changes in the portal circulation in patients with cirrhosis to understand better their potential role in PVT development (figure 1). The hypothesis was that local inflammatory responses, for example, related to bacterial translocation products¹⁸ lead to endothelial activation with the release of prohaemostatic proteins such as von Willebrand factor and factor VIII,¹⁹ and to local activation of platelets and coagulation (appendix p 3).^{20–22} However, a study by Driever and colleagues²³ has questioned the existence of a relative hypercoagulable state in the portal circulation having analysed markers of inflammation and coagulation activation in samples taken from the portal vein, the hepatic vein, and the jugular vein in patients with cirrhosis. Although markers of activation of endothelial cells, platelets, and coagulation were higher in the portal vein than in the hepatic vein, the difference in levels of these markers between the portal vein and the jugular vein was, at most, modest. The authors concluded that comparison of markers from the portal vein with that of the hepatic vein might erroneously lead to the conclusion that the portal circulation in patients with cirrhosis is hypercoagulable, as the difference between levels of haemostatic markers between the portal and hepatic vein is explained mainly by hepatic clearance of these markers. Likewise, Rahr and colleagues²⁴ observed that in patients without liver disease undergoing gastric surgery for benign disease, one marker of coagulation activation (fibrinopeptide A) was higher in portal blood than in systemic blood, although other markers did not differ. Although the study by Driever and colleagues²³ has different conclusions from previous works and has been criticised, other observations argue against the concept of the cirrhotic portal vein as an inflammatory and hypercoagulable entity. First, in a prospective study by Turon and colleagues²⁶ assessing risk factors for the development of PVT in patients with cirrhosis, markers of haemostasis and inflammation were not identified as predictors for PVT development. Instead, markers of portal hypertension fully explained the risk for PVT development. Second, the Lisman group showed that portal vein thrombi are often missing classical

haemostatic components such as platelets and fibrin.¹⁶ Finally, portal vein thrombi are characterised by intimal hyperplasia of the portal vein wall, which can result from changes in portal vein pressure rather than from activation of coagulation or the evolution of a former thrombus.

PVT in patients without cirrhosis

Causes and underlying mechanisms

The prevalence of acquired and inherited risk factors for PVT in the absence of cirrhosis was reviewed in 2019 by Hernández-Gea and colleagues²⁷ and is summarised in the appendix (p 23). Multiple risk factors were found in 15–36% of the patients with PVT, suggesting that investigators should systematically perform comprehensive screening for risk factors for thrombosis.²⁷ In up to 30% of the patients with PVT, no risk factor for thrombosis is identified. Data from the last 10 years have clarified the role of some new risk factors, including central obesity,²⁸ SARS-CoV-2 infection or vaccination (rarely),^{29–31} cytomegalovirus infection,³² and clonal haematopoiesis.³³ Obesity is present in 25% of patients with one or more risk factors for thrombosis and 45% with idiopathic PVT in the absence of cirrhosis.²⁸ In multivariate analysis, an increased waist circumference was the strongest variable associated with idiopathic PVT.²⁸ Cytomegalovirus disease can be associated with PVT with similar severity and evolution as patients without cytomegalovirus disease, but with much higher association with the prothrombin G20210A gene variant (22%) than without (4%), suggesting that these entities act synergistically to promote thrombosis.³²

Although myeloproliferative neoplasm is the most common risk factor for PVT, the underlying mechanisms are unknown. Recent data have clarified the link between *JAK2*^{V617F} mutation—the most commonly found mutation in patients with both PVT and myeloproliferative neoplasm—and thrombosis. Both endothelial cells and endothelial progenitors can harbour *JAK2*^{V617F} mutation; *JAK2*^{V617F} mutated endothelial cells display increased P-selectin and von Willebrand factor expression, and favour leucocyte adhesion and venous thrombi formation.³⁴ Mathematical models from a 2022 paper showed that *JAK2*^{V617F} mutation occurs early in life, explaining the young age of patients with myeloproliferative neoplasm and PVT in the absence of cirrhosis.³⁵ Other complex mechanisms contributing to the increased risk of thrombosis in myeloproliferative neoplasm, involving all blood cell types and plasmatic factors, have been reviewed by Guy and colleagues.³⁴ Next-generation sequencing data have highlighted clonal haematopoiesis of indeterminate potential (CHIP) as a risk factor for PVT in the absence of cirrhosis. CHIP is due to the presence of clonally expanded hematopoietic stem cells caused by high molecular-risk variants (*TET2*, *DNMT3A*, *ASXL1*, *TP53*, etc) in individuals without evidence of haematological malignancy. These variants

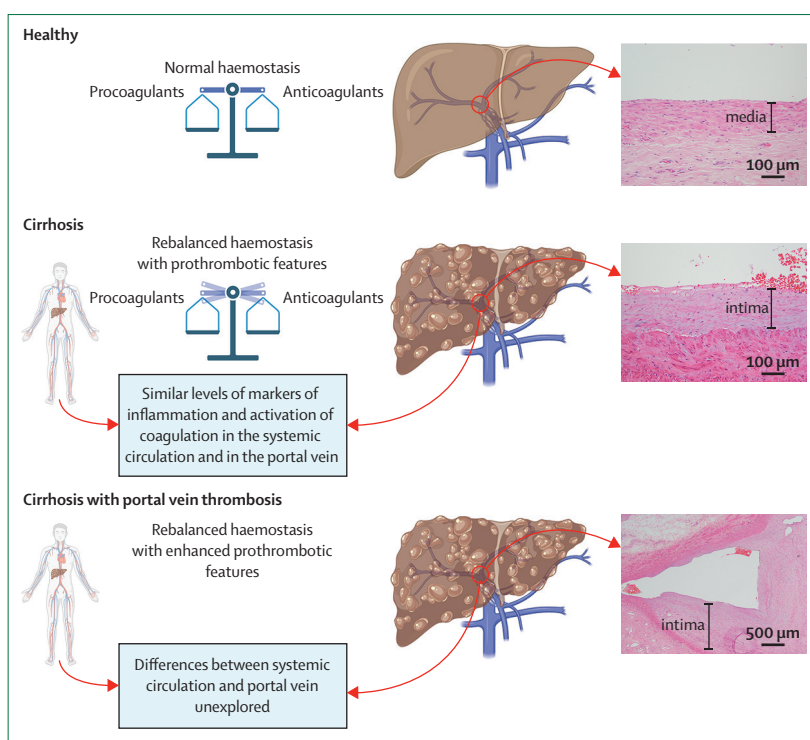


Figure 1: Haemostasis and the portal vein wall in healthy individuals, patients with cirrhosis, and patients with cirrhosis and PVT

PVT=portal vein thrombosis.

accumulate with age and favour arterial and venous cardiovascular complications and the development of haematological malignancies.³³ A first study, using molecular profiling in patients with myeloproliferative neoplasm and PVT in the absence of cirrhosis, showed that the presence of *TP53* variants, a high *JAK2* allele burden (>50%), or both is predictive of worse haematological prognosis (myelofibrosis, acute leukaemia, or death).³⁶ In a second study, next-generation sequencing profiling in 55 patients with idiopathic PVT revealed that 25 had high molecular-risk variants. These variants were associated with an increased risk for recurrent thrombosis.³⁷ Thus, molecular profiling by next generation sequencing in patients with PVT in the absence of cirrhosis seems helpful for identifying underlying causes and adjusting treatment strategies based on prognostic stratification.

Pathophysiology of portal hypertension

Increased resistance to portal blood flow is the main pathophysiological mechanism leading to the development of portal hypertension in patients with cirrhosis or in those with PVT in the absence of cirrhosis. The pathophysiology of portal hypertension in cirrhosis has been extensively reviewed and discussed (appendix p 24).³⁸ The increase in resistance is mainly located at the intrahepatic level and has two main components: structural and dynamic (due to an increase in intrahepatic

(Prof A Shukla); Service de Chirurgie Viscérale, Hôpitaux Universitaires de Genève, Geneva, Switzerland
(Prof C Toso); Department of Liver and Hepato-Pancreato-Biliary Unit, Queen Elizabeth Hospital, University Hospitals Birmingham, Birmingham, UK (Prof D Tripathi); Institute of Immunology and Immunotherapy, University of Birmingham, Birmingham, UK (Prof D Tripathi)

Correspondence to: Prof Pierre-Emmanuel Rautou, Service d'Hépatologie, AP-HP Hôpital Beaujon, 92110 Clichy, France
Pierre-emmanuel.rautou@inserm.fr

See Online for appendix

vascular tone). Once portal hypertension is present, portosystemic collaterals, trying to decompress the portal venous system, develop. However, the concomitant development of splanchnic and systemic vasodilation, by increasing portal blood flow, maintains or even aggravates portal hypertension despite the formation of these collaterals. Vasodilation of the systemic and splanchnic beds promotes an effective hypovolaemia that triggers the activation of vasoactive systems (eg, renin, angiotensin, aldosterone) that, by promoting sodium and water retention, expands plasma volume trying to refill the vascular bed. Expansion of plasma volume facilitates the maintenance of an increased portal blood flow. The activation in intrahepatic vasoactive systems further increases intrahepatic vascular tone, closing a vicious circle and maintaining portal hypertension (appendix p 24).

In patients with PVT in the absence of underlying liver disease, the increased resistance to portal blood flow is exerted by the occlusion of the portal venous system by the thrombus (appendix p 24). Thrombosis does not require the occlusion of the entire vessel to produce a marked increase in resistance and portal hypertension. Thus, according to Poiseuille's law, a reduction of just 50% of the vessel lumen already leads to a marked increased pressure gradient.²⁷

Similar to patients with cirrhosis and portal hypertension, patients with PVT and no underlying chronic liver disease can develop portosystemic collaterals. However, these patients also develop porto-portal collaterals that bypass the obstruction and reach the intrahepatic portal circulation, helping to decompress the system and perfuse the liver. These porto-portal collaterals are very rare in patients with portal hypertension secondary to increased resistance at the intrahepatic level (eg, cirrhosis or porto-sinusoidal vascular disorder). The potential effect of the presence and magnitude of these porto-portal collaterals perfusing the liver on the natural history of PVT in the absence of cirrhosis is unknown.

Unfortunately, there is a scarcity of good experimental models of chronic PVT. The most studied experimental model of prehepatic portal hypertension is the partial portal vein ligated rat or mouse model. Both of these models develop an extensive network of portosystemic collaterals (more than 90% portal blood flow shunted a few days after the portal vein ligation procedure) that is associated with rapid development of splanchnic and systemic vasodilation and sodium and water retention.^{39,40} However, contrary to what happens in patients with chronic PVT, no or only minor porto-portal collaterals develop.

Some small preliminary studies suggested that patients with PVT in the absence of cirrhosis had similar systemic vasodilation as patients with cirrhosis.^{41,42} However, a study including 39 patients with PVT in the absence of cirrhosis and 39 with compensated cirrhosis, matched on the severity of portal hypertension and liver dysfunction,

showed that despite some patients having hyperdynamic circulation, the mean cardiac index and systemic vascular resistance values of the two cohorts of patients were within the range of values observed in healthy people.⁴³ This finding is in line with another well-described finding in patients with cirrhosis,⁴⁴ showing that a hyperdynamic circulation appears and progressively aggravates in relation to the severity of portal hypertension and liver dysfunction. Currently, there is an absence of clinical data to determine whether vasoactive systems are activated or if there is plasma volume expansion in patients with PVT in the absence of cirrhosis. Furthermore, the potential implications of these changes in the context of developing portal hypertension-related complications remain unexplored.

A pioneering study in a small group of patients with PVT in the absence of cirrhosis showed that propranolol is, as it is shown in patients with cirrhosis, able to reduce azygos blood flow.⁴⁵ Because portal pressure is challenging to measure in patients with PVT in the absence of cirrhosis, reduction in azygos blood flow—an index of porto-collateral blood flow—is considered a surrogate of the potential use of propranolol in these patients. However, as previously stated, hyperdynamic circulation is not a universal finding in patients with PVT in the absence of cirrhosis. The absence of a hyperdynamic circulation could affect the capacity of non-selective beta blockers such as propranolol to reduce portal hypertension (not shown in PVT but shown in cirrhosis).⁴⁶ Of note, in patients with cirrhosis, carvedilol is more effective in decreasing the hepatic vein pressure gradient than propranolol,⁴⁷ supposedly because carvedilol reduces portal blood flow and intrahepatic resistance. Because the increase in intrahepatic resistance in PVT is due to the occlusion at the portal vein level, there is no clear rationale supporting a higher efficacy of carvedilol over propranolol in reducing portal pressure in patients with PVT.

Non-invasive tests versus liver biopsy

In clinical practice, the main challenge is to identify patients with cirrhosis from those without to enable cirrhosis-specific management (particularly regarding surveillance for hepatocellular carcinoma [HCC]). The workup for evaluating underlying liver disease at PVT diagnosis should include a CT scan and liver stiffness measurement, to determine cirrhosis. A liver biopsy is not necessary when the suspicion of cirrhosis is high, namely in patients with at least one risk factor for cirrhosis and either segment IV atrophy together with a nodular liver surface or liver stiffness measurement greater than 20 kilopascals (kPa). A liver biopsy is generally unnecessary when there are no indicators of underlying liver disease (normal liver blood test, normal liver morphology, and normal liver stiffness measurement). However, liver biopsy should be considered when

porto-sinusoidal vascular disorder or other chronic liver diseases are suspected (appendix p 25).

In patients with PVT in the absence of cirrhosis, liver stiffness measurement obtained through either transient^{43,48,49} or two-dimensional shear wave elastography,⁵⁰ while generally elevated compared to healthy volunteers, is usually less than 10 kPa. An animal study showed that 50%, 80%, and 100% portal vein occlusion (generated by insertion and inflation of a balloon catheter) lead to a decrease in liver stiffness (measured using magnetic resonance elastography) of 0.8%, 7.7%, and 12.3%, respectively.⁵¹ These findings suggest that PVT does not markedly affect liver stiffness measurement values. In case-control studies comparing patients with cirrhosis with patients with either PVT in the absence of cirrhosis^{43,48,49} or porto-sinusoidal vascular disorder,^{43,52,53} a liver stiffness measurement of more than 20 kPa was specific to patients with cirrhosis. In addition, although liver stiffness measurement is higher in patients with porto-sinusoidal vascular disorder than in those with PVT in the absence of cirrhosis,⁴³ it cannot discriminate between the two conditions.

Liver morphological changes can help discriminate cirrhosis from PVT in the absence of cirrhosis or porto-sinusoidal vascular disorder. Cirrhosis is associated with caudate lobe hypertrophy, segment IV atrophy, and a nodular liver surface.^{54,55} In chronic PVT, liver morphology is normal at early stages, while peripheral atrophy, segment IV hypertrophy, or both, can appear later.⁵⁶ In long-standing PVT in the absence of cirrhosis, the liver surface can be nodular in 20% of patients.⁵⁷ PVT can occur in patients with porto-sinusoidal vascular disorder.⁵⁸ However, no CT scan feature can help discriminate patients with PVT and porto-sinusoidal vascular disorder from those with PVT and a normal liver.⁵⁹⁻⁶²

The usefulness of serum biomarkers of fibrosis has not been evaluated in PVT.

Effect of aetiological therapy

In patients with PVT in the absence of cirrhosis, data on controlling the identified risk factor for thrombosis recurrence are scarce. In myeloproliferative neoplasm, several studies investigated the effect of controlling the haematological disease on venous thrombosis recurrence, mainly focusing on patients with a history of thrombosis outside the splanchnic vascular bed.⁶³⁻⁶⁷ In these patients, studies evaluating the effect of cytoreductive treatment on thrombosis recurrence gave inconsistent results.⁶⁸ A 2018 paper presented a pooled analysis of 565 patients with myeloproliferative neoplasm-related venous thromboembolism and explored the role of hydroxyurea (hydroxycarbamide) in combination with aspirin or oral anticoagulants. Oral anticoagulation was independently associated with lower thrombosis recurrence, whereas hydroxyurea was not.⁶⁹ By contrast, in a 2021 systematic review of 1235 patients with myeloproliferative neoplasm, the combination of cytoreduction

with vitamin K agonists or direct oral anticoagulants was more effective in preventing recurrence of venous thromboembolism than vitamin K agonists or direct oral anticoagulants alone.⁷⁰ In patients with myeloproliferative neoplasm and splanchnic vein thrombosis, the effect of cytoreductive treatment on the risk of recurrence of PVT is unclear. Hydroxyurea did not significantly decrease the rate of recurrent thrombosis in a subgroup analysis of a systematic review of 218 patients, including 180 with PVT.⁶⁹ A small prospective study evaluated the effect of pegylated interferon alfa-2a in 20 patients with myeloproliferative neoplasm and PVT.⁷¹ PVT did not recur in any of the patients during a median follow-up of 2.2 years. Another small retrospective case series, including 18 patients with myeloproliferative neoplasm and PVT, found no recurrence of thrombosis after 2 years of treatment with ruxolitinib.⁷² In summary, the benefit of adding hydroxyurea to oral anticoagulation to prevent thrombosis recurrence remains uncertain, particularly in patients with PVT. Preliminary studies suggest that pegylated interferon and ruxolitinib could effectively prevent thrombosis recurrence in patients with myeloproliferative neoplasm and PVT.

The effect of eculizumab on thrombosis recurrence in splanchnic vein thrombosis caused by paroxysmal nocturnal haemoglobinuria has been evaluated. In one observational study, including 62 patients, 42 were treated with eculizumab and 20 were not treated with eculizumab. A new thrombosis in the splanchnic or extra splanchnic territory occurred less frequently in patients treated with eculizumab than those without.⁷³

In inflammatory bowel diseases, the inflammatory response leads to a hypercoagulable state, substantially increasing the risk of venous thromboembolism. It has been suggested that 5-aminosalicylic acid and infliximab could reduce the risk of venous thrombosis (outside the splanchnic territory),⁷⁴ indicating that bowel disease control is associated with a decreased risk of thrombosis. Whether these results also apply to PVT recurrence remains unknown.

Regarding Behçet's disease, it has been suggested that treatment with steroids or immunosuppressive agents decreases the recurrence of thrombosis and liver-related events in patients with Budd–Chiari syndrome.^{75,76} Data specifically on PVT in Behçet's disease are lacking.

Altogether, these data support either the treatment or the removal of associated risk factors when identified. However, data are still lacking to support anticoagulation interruption when the cause of PVT is well controlled.

Anticoagulation in patients with recent and chronic PVT in the absence of cirrhosis

A multicentric European cohort study of people with recent PVT showed that anticoagulation with low molecular weight heparin (LMWH) followed by vitamin K agonists led a low rate of mesenteric infarction (2%) and recanalisation of the portal vein in

40% of patients.⁵ Baveno VII recommendations indicate that anticoagulation should be started at a therapeutic dose immediately after diagnosis of recent PVT.⁷⁷ LMWH is widely accepted in this situation. Unfractionated heparin should be used cautiously, as a high prevalence of heparin-induced thrombocytopenia has been reported in this population.⁷⁸ Although data are limited, direct oral anticoagulants can be considered a primary option in patients without so-called triple positive antiphospholipid syndrome or features of intestinal ischaemia.⁷⁷ A retrospective study in 330 patients with recent PVT in the absence of cirrhosis showed that direct oral anticoagulants were associated with similar rates of recanalisation as LMWH and higher rates than warfarin derivatives.⁷⁹ Moreover, the risk of major bleeding was significantly lower with direct oral anticoagulants than with warfarin. In this study, most patients had a local risk factor for thrombosis, and only 11% had an myeloproliferative neoplasm.

In chronic PVT in the absence of cirrhosis, the approach varies according to associated risk factors for thrombosis (appendix p 26). In patients with at least one strong risk factor for thrombosis recurrence, namely antiphospholipid syndrome, myeloproliferative neoplasm, or personal or first-degree history of spontaneous venous thromboembolism, long-term anticoagulation is recommended. In patients without a strong risk factor for thrombosis recurrence, a randomised open-label controlled trial showed that rivaroxaban 15 mg once daily reduced the recurrence of thromboembolic events or death without increasing the occurrence of major bleeding.⁸⁰ In patients in whom anticoagulation was discontinued, a D-dimer concentration of less than 500 ng per mL (measured with the Innovance technique, Siemens [Munich, Germany]) 1 month after anticoagulation interruption predicted a low risk of recurrence.⁸⁰ On the other hand, an observational study gathering 134 patients with PVT in the absence of cirrhosis and no strong risk factor for thrombosis, factor VIII concentration equal to or greater than 150% was predictive of recurrent thrombosis.⁸¹ Thus, although long-term anticoagulation is broadly recommended in patients with chronic PVT in the absence of cirrhosis, the challenge is identifying populations that do not need such long-term treatment. Next-generation sequencing, D-dimers, and factor VIII could be helpful in this situation.^{37,80}

Variceal bleeding in patients with PVT

In patients with recent PVT, gastro-oesophageal varices can develop as soon as PVT occurs and can progress during the first year of follow-up.⁸² Screening for varices should thus be performed in patients with recent PVT, and endoscopy should be repeated 1 year after PVT diagnosis in the absence of recanalisation.⁷⁷ Non-invasive methods, including liver stiffness measurement, are not accurate enough to replace endoscopy in this setting.⁴⁸

Spleen stiffness measurement seems promising, but further studies are needed.^{48,50}

In patients with chronic PVT in the absence of cirrhosis, bleeding is the most frequent complication of portal hypertension. In a study of 178 patients with PVT in the absence of cirrhosis, bleeding was the first manifestation of PVT in 15% of patients, and occurred in 16% of patients during the follow-up period.⁸³ As seen in patients with cirrhosis, the presence of large oesophageal varices is an independent predictor of variceal bleeding.⁸³ Despite secondary prophylaxis, rebleeding occurs in up to 47% of patients within 5 years of the first bleeding episode.^{83,84} Sarcopenia was associated with a higher risk of refractory variceal bleeding in a study of 51 patients with chronic PVT in the absence of cirrhosis.⁸⁵ Conversely, anticoagulant therapy was not associated with a higher risk of variceal bleeding.^{80,83} Endoscopic band ligation seems safe in patients with chronic PVT in the absence of cirrhosis without interrupting vitamin K agonists, based on an assessment of 471 endoscopies in that setting.⁸⁶ Given these findings, recommendations for patients with cirrhosis could be applied to patients with chronic PVT in the absence of cirrhosis with acute variceal bleeding and for primary or secondary prophylaxis of variceal bleeding.⁷⁷

Portal vein recanalisation with or without a transjugular intrahepatic portosystemic shunt (TIPS) procedure has been performed in patients with portal-hypertension related bleeding not controlled with endoscopic therapy.⁸⁷⁻⁹¹ The rebleeding rate in patients with patent stents is less than 10%.⁸⁹⁻⁹¹

Portal cholangiopathy

Portal cholangiopathy is broadly defined as biliary ductal and gallbladder wall abnormalities in patients with PVT in the absence of cirrhosis and portal cavernoma.⁹² Portal cholangiopathy develops due to collateral formation around the biliary system, which causes compression of bile ducts, ischaemic bile duct injury, chronic inflammation, and fibrosis, which can in turn lead to stricture formation.⁹³ Despite an 80–100% prevalence of portal cholangiopathy at magnetic resonance cholangiography,^{93,94} only 5–15% of patients develop symptoms after a median duration from diagnosis of PVT of 7 years (range 0–24 years).⁹³⁻⁹⁶ Whether portal cholangiopathy can progress over time remains debated.^{94,97} The clinical stages of portal cholangiopathy have been conventionally divided into asymptomatic and symptomatic, including abdominal pain, jaundice, and cholangitis.^{96,98} The cholangiographic findings include extrinsic impressions or indentations, shallow impressions or indentations, irregular ductal contour, stricture, upstream dilatation, filling defects, bile duct angulation, and ectasia.^{92,94,96} Classification of portal cholangiopathy is based on the severity of biliary changes: no abnormalities (grade 0); irregularities or angulations of the biliary tree (grade 1); indentations or strictures without dilatation (grade 2); strictures with dilatation (extrahepatic

duct >7 mm, intrahepatic duct >4 mm; grade 3). Currently, intervention is not based on these biliary changes and is restricted to symptomatic patients only. Following multidisciplinary discussion, treatment options include ursodeoxycholic acid, endoscopic biliary drainage, radiological portal vein recanalisation, and surgery, either alone or combined. Most patients with symptomatic portal cholangiopathy are managed endoscopically to remove biliary stones, with good long-term outcomes.^{96,99} Sphincterotomy and ductal clearance (balloon or basket) are feasible, although haemobilia can occur.¹⁰⁰ Endoscopic stent placement (plastic or self-expandable metal stent) is usually needed for stenosis.^{99–101} Radiological portal vein recanalisation is increasingly used to treat patients with symptomatic portal cholangiopathy, with promising results when performed in expert centres.^{87,90} Biliary dilatation can be treated with endoscopic retrograde cholangiopancreatography before recanalisation to decrease the risk of haemobilia. Surgical approaches have also been proposed, including portosystemic shunt followed by hepatico-jejunostomy,^{100,102,103} but are increasingly replaced by interventional radiology techniques.

Mesenteric ischaemia

PVT can extend to the mesenteric vein and lead to acute mesenteric ischaemia in 4–58% of the patients, with a mortality ranging from 10–45%.^{5,104–106} Factors associated with intestinal resection in patients with acute mesenteric vein thrombosis include diabetes mellitus (suggesting an arteriosclerosis-related component) and thrombus extension to the small venules.¹⁰⁵ As there is no accurate clinical or laboratory sign, diagnosis of acute mesenteric ischaemia relies on CT, particularly signs of intestinal injury including wall thickening, decreased or absent contrast enhancement, bowel dilatation, pneumatosis intestinalis, or portal venous gas.⁴ A multiphase CT scan protocol, including unenhanced, arterial, and venous phase images, without a positive oral contrast agent, and excellent CT image quality improves the interobserver agreement of imaging features of acute mesenteric ischaemia and diagnostic accuracy.^{4,107,108} No randomised clinical trial has ever been performed in acute mesenteric ischaemia, and treatment is based on preclinical and observational studies. First-line medical treatments provided in expert centres includes early anticoagulation, bowel rest, proton pump inhibitors, and broad-spectrum oral antibiotics, with reported low rates of intestinal necrosis and death.^{109–113} Intestinal surgical resection followed by delayed anastomosis is indicated in transmural necrosis.^{104,109} In a prospective study of 67 patients with arterial and venous acute mesenteric ischaemia, organ failure, plasma lactate levels greater than 2 mmol per L, and small bowel dilatation greater than 2.5 cm on CT scan were independent predictors of transmural intestinal necrosis requiring surgical resection and could help select patients requiring surgery.¹⁰⁸

However, these factors are more accurate for patients with arterial mesenteric ischaemia than in those with venous acute mesenteric ischaemia.¹⁰⁸ Thrombolytic therapies have only been evaluated in small case series (reviewed in a recent meta-analysis¹¹⁴ with a moderate rate [around 20%] of vein recanalisation but a high risk [around 90%] of bleeding).^{104,115–118} Based on these preliminary data, thrombolytic therapy can be carefully evaluated in experienced centres for selected patients who are clinically deteriorating despite medical therapy to avoid laparotomy and intestinal resection. Although the evidence is scarce, patients with a history of acute mesenteric ischaemia are considered to have an indication for long-term anticoagulation therapy.⁷⁷

Chronic abdominal pain

Patients with chronic PVT might have chronic or recurrent abdominal pain. Contrast-enhanced CT should be performed to rule out the recurrence of thrombosis, particularly in the small collaterals or tributaries. In rare cases, mesenteric vein thrombosis has been associated with intestinal stricture because of previous intestinal ischaemia.¹¹⁹ Diagnosis is based on symptomatology of small bowel occlusion, and visualisation of benign small bowel stenosis at imaging (CT enteroclysis). Finally, chronic abdominal pain has been reportedly associated with portal cavernoma alone, in the absence of obvious recurrent thrombosis. The effect of portal vein recanalisation on these symptoms is debated.^{87,90} Exceptional cases of protein-losing enteropathy (via portal hypertension related impaired lymphatic drainage or intestinal hyperpermeability^{120,121}) have been reported in patients with portal cavernoma.⁸³

Interventional radiology

Despite the rapid introduction of anticoagulation in patients with recent PVT, complete recanalisation occurs in 40% of the patients, and the development of portal hypertension is likely. Moreover, data show that the outcome of patients with PVT associated with *JAK2*^{V617F} mutation is poor despite anticoagulant treatment, suggesting that additional treatment options are needed.^{117,122} Accordingly, portal vein recanalisation using interventional radiology has been proposed in patients with PVT whose clinical features suggest a low probability of recanalisation, a high risk of mesenteric ischaemia, or both. Results reported so far show that this approach is feasible and that higher recanalisation rates than anticoagulation alone can be achieved.^{117,123–132} It might lead in the long term to lower incidence of portal hypertension-related complications. However, severe procedure-related morbidity and fatalities have been reported when using thrombolytics (appendix p 4).^{117,123–132} Large prospective multicentre studies are needed to determine the benefit–risk ratio of this approach.

In patients with chronic PVT in the absence of cirrhosis, portal vein recanalisation with or without TIPS

has been used exponentially over the last decade. Modern imaging modalities delineating the venous anatomy and improved technical approaches to the thrombosed venous system have revolutionised the interventional radiology approaches to portal cavernoma and opened the possibility of providing definitive portal decompressive treatments.^{133,134} Recognised indications for this approach include variceal bleeding recurring despite non-selective beta blockers and band ligation and symptomatic portal cholangiopathy. Cases of patients with difficult to treat ascites, chronic abdominal pain, enteropathy treated with portal vein recanalisation, or a combination, have also been reported (appendix p 7).^{87,89–91,116,125,135–138} High technical success rates have been reported by expert teams, associated with good control of the symptoms, with evidence indicating that recanalisation might also improve muscle mass.⁸⁷ Patients are placed under general anaesthesia (appendix p 27), then the venous system can be accessed via transjugular, percutaneous transhepatic, transplenic, or transmesenteric routes depending on the morphology of the occlusion, the quality of the inflow and outflow, and the anticipated need to place a TIPS. Contrast injection of the splenomesenteric system identifies the remnant portal vein cord and shows the extent of the occlusion to the portal tributaries and intrahepatic branches. The occlusion is crossed with catheters and guidewires, with the help of balloons. Often, a snare is advanced and used to facilitate through-and-through access. From there, liberal use of portal, splenic, or mesenteric stents is performed along with completion TIPS if needed, ensuring prompt inflow and outflow. Varices might be embolised during the procedure to minimise future risk of bleeding and maximise hepatopetal flow.^{87,90} After the procedure, the maintenance and duration of anticoagulant therapy are decided on a case-by-case indication.

Specific issues

Effect on quality of life

Patients with PVT in the absence of cirrhosis are usually young and economically active people who could experience health selection effects and social inequalities due to their PVT. Moreover, PVT diagnosis can be associated with diagnostic conundrum due to the rarity of the disease, and recognising associated underlying thrombophilic disorders can be challenging, leading to diagnostic delays and uncertainty. The development of portal hypertension brings anxiety,¹³⁹ work-related disability due to the necessary multiple hospital visits and interventions, fear of complications, and social stigmatisation.^{140–143} Understanding the effect of PVT on health-related quality of life (HRQoL) will allow the identification of relevant patient-related outcomes (PROs) and the incorporation of patient-centred care into clinical practice. The most widely used generic HRQoL questionnaires are the 12 item and 36 item short form

surveys, focusing on disease-related variables without addressing the social effects and adopting a patient-centred perspective. However, in the field of PVT, patients face specific problems that are not well reflected in these generic questionnaires.

One study evaluated HRQoL in PVT (either with or in the absence of cirrhosis) and found that PVT was associated with new onset depression and anxiety.¹⁴⁴ Future studies on HRQoL in PVT should identify meaningful PROs that can be combined with clinical markers for a comprehensive assessment of treatment effectiveness that in turn can be a direct measure of success for high-quality patient-centred care. Identifying relevant PROs is an unmet need where the involvement of patient associations will be crucial.

Fertility, contraception, and pregnancy

Fertility, contraception, and pregnancy are frequent and relevant issues among patients with PVT as women of childbearing age account for 20% of the PVT patient population and their 5-year survival rate is above 90%.⁵ The prevalence of infertility in patients with PVT is unknown. In the general population, contraception and pregnancy are associated with a hypercoagulable state with increased activity of procoagulant factors, a decrease in particular natural anticoagulant factors, and fibrinolysis.^{145,146} Accordingly, women taking oral contraception containing oestrogens are at increased risk of venous thromboembolism outside the splanchnic territory (three-fold higher risk during the first year of use).^{146–148} There is little evidence for the role of oral contraception in PVT development. Indeed, the proportion of women with a recent diagnosis of PVT taking oral contraception varies from 5–50% and is frequently associated with other prothrombotic conditions.^{5,149} Nevertheless, in women with known PVT, contraception containing oestrogen should be avoided and progestogen-only oral contraception or an intrauterine device should be preferred. In the general population, during pregnancy and postpartum there is a five-fold increased risk of venous thromboembolism.^{146–148} Whether pregnancy also favours PVT is unclear, as only rare cases of pregnancy revealing PVT have been reported.¹⁵⁰

The outcome of pregnancy in women with PVT is typically good when the disease is treated and well-controlled.^{151,152} Pregnancy should be planned, and a preconception visit is recommended to inform the patient about the risks of pregnancy with PVT, ensure portal hypertension and underlying prothrombotic factors are controlled before conception, and adjust drug prescription.^{152,153} Five studies assessed the outcome of pregnancy in a total of 260 women with known and controlled PVT.^{149,151,154–156} There was no maternal death, and the rate of live births was high (about 85%, comparable to that in a general population). However, the rates of prematurity (11%) and fetal death (2%) appeared to be higher than in the general population.

Concerning maternal outcomes, no splanchnic vein rethrombosis was observed, but the rate of pre-eclampsia was high (4%), supposedly explained by thrombotic occlusion of the placenta circulation, especially in women with underlying prothrombotic disorders. Bleeding related to portal hypertension is a rare complication during pregnancy when adequate prophylaxis has been provided (3% haemorrhages, 50% without adequate prophylaxis).¹⁵⁷ Overall, pregnancy should not be contraindicated if the PVT and underlying thrombotic factors are controlled.

PVT in children: specificities as compared with adults

PVT is the most common cause of portal hypertension in children and differs from PVT in adults in its causes, clinical presentation, and management. In paediatrics, chronic PVT is the most common presentation. Recent PVT is rarely diagnosed, but diagnoses are typically in premature infants in neonatal ICUs where Doppler ultrasound is often performed routinely after umbilical venous catheter placement. Growth retardation is an important and common manifestation of PVT in children.¹⁵⁸ The most common risk factor for the development of chronic PVT in children is an umbilical venous catheter placed in the neonatal period.¹⁵⁹ When there is no history of such a catheter, the cause usually remains unclear. History might reveal an episode of profound dehydration, exchange transfusion, or sepsis. Thrombophilia workup usually does not reveal a general risk factor for thrombosis. Rarely, in children, recent splenectomy could be a cause of acute PVT. When an umbilical venous catheter is incriminated, the left portal vein is most often involved, with the main portal vein spared.¹⁶⁰ When a thrombus in the main portal vein goes unnoticed, the patient has subclinical, cavernous transformation of the portal vein that ultimately can present as portal hypertension between 2 and 17 years with one or more of the following symptoms: haematemesis, splenomegaly, thrombocytopenia, or, rarely, liver nodules in the absence of parenchymal liver disease.^{159,161}

Management of a child with PVT depends on their age at presentation. In case of neonatal evidence of main portal obstruction, LMWH is considered but should be balanced against the risk of intracranial bleeding. Catheter-directed thrombolysis for recent PVT has been successfully attempted in children aged 3–17 years.¹⁶¹ In the setting of chronic PVT, the preferred method is to perform a meso-Rex shunt (appendix p 28) because it restores the blood flow to the liver and should be considered pre-emptively.^{162,163} This approach is only possible if the Rex recessus is permeable and wide enough, associated with left–right portal flow documented on retrograde portal venogram.¹⁶⁴ When the Rex recessus is not permeable and the patient presents with complications of portal hypertension, splenorenal or mesocaval shunts are palliative, but expose the patient to the long-term complications of portosystemic bypass.^{165,166} Liver

transplantation can be considered in rare circumstances and on a case-by-case basis if life-threatening extrahepatic complications such as pulmonary vascular disease mandate restoration of portal flow (panel 1).

In children with recent PVT, in case of partial or complete isolated left portal vein thrombosis, watchful

Panel 1: Management of portal vein thrombosis in children

Risk factors

- Umbilical venous catheter
- Omphalitis or sepsis of abdominal origin
- Exchange transfusion
- Dehydration
- Thrombophilia (rare)

Clinical presentation: diagnostic delay is frequent

- Splenomegaly or hypersplenism
- Haematemesis
- Haemorrhoids
- Liver nodules
- Growth retardation

Diagnostic imaging

- Ultrasound coupled with Doppler
- Contrast-enhanced CT

Pre-therapeutic imaging

- Retrograde portal venogram
 - Patent or dominant main portal vein
 - Rex recesses permeability (for surgical planning)
 - Left-right portal flow
- Direct portal venogram (rarely)
 - Patent or dominant main portal vein
 - Angioplasty access and feasibility (in experienced centres)

Management of chronic PVT

- Watch for consequences of portal hypertension and portosystemic bypass
- If Rex permeable: consider pre-emptive reportalisation according to local resources
- If Rex not permeable: watch and wait for complications
- If life-threatening portal hypertension-related complications: perform surgical shunt (distal splenorenal preferred)

Long-term follow-up

- Rex shunt performed
 - Follow annually for signs of portal hypertension (platelet count, Doppler)
 - Invasive imaging and angioplasty in the case of suspected stenosis
- Cavernoma—no surgical shunt
 - Monitor for complications of portal hypertension
- Other surgical shunts
 - Monitor for complications of portal hypertension and portosystemic bypass
 - Monitor for growth-related changes in the shunt

management is usually preferred. If the thrombus extends to both portal branches or the main portal vein systemic heparin-based anticoagulation is considered, weighing the benefits against the risks of intracranial bleeding in this at-risk population.¹⁶⁰ In children with recent PVT following a splenectomy, directed thrombolysis has shown promising results in experienced centres.¹⁶¹ There is no evidence or consensus on primary or secondary prophylaxis of oesophageal varices in children.

PVT in patients with cirrhosis

Epidemiology and risk factors

A meta-analysis revealed a pooled prevalence of PVT of 14% in patients with cirrhosis and a pooled incidence of 4.6 % per 100 patient-years.¹⁶⁷ Prevalence increases with the severity of cirrhosis.⁶ 50% of cases of PVT are diagnosed at the time of liver transplantation.¹⁶⁸ PVT in patients with cirrhosis has been consistently associated with features reflecting the severity of portal hypertension, namely high-risk oesophageal varices, history of variceal bleeding, presence of ascites, and lower platelet count.^{26,167,169,170} The association of PVT with the following features remains debated: a decrease in portal blood flow velocity,^{26,169,170} non-selective beta-blockers,^{26,171,172} plasma D-dimer concentrations,²⁶ inflammation reflected by plasma interleukin (IL-6) concentration, or neutrophil-to-lymphocyte and platelet-to-lymphocyte ratios,^{173–175} features of the metabolic syndrome including higher body mass index, obesity, and diabetes.^{26,171,176–178} Although suggested by previous retrospective case series,¹⁷⁹ PVT in cirrhosis has not been associated with the ABO blood group^{180,181} nor inherited thrombophilia^{26,169,182} in large prospective cohorts (appendix p 29).

Effect of aetiological treatment

Removal or suppression of the primary causal factor in cirrhosis includes hepatitis C virus (HCV) cure, hepatitis B virus (HBV) suppression in the absence of hepatitis D virus (HDV) infection, and abstinence from alcohol. Besides improving hepatic function, these measures ameliorate portal hypertension, thereby reducing the risk of decompensation of cirrhosis.⁷⁷ The definition and effect of the removal or suppression of the primary causal factor in patients with cirrhosis unrelated to viral hepatitis or alcohol is less well established, which does not necessarily imply that the respective therapies (eg, phlebotomy for haemochromatosis) are less effective in modifying the disease course.

Sustained virological response (SVR) following HCV direct-acting antiviral therapy provided an unprecedented opportunity to study the effect of removing the primary causal factor on PVT development in patients with cirrhosis. In this context, the effect of SVR on Virchow's triad of components that contribute to development of thrombosis, namely haemodynamic changes, endothelial dysfunction, and hypercoagulability,

can be considered. The hepatic venous pressure gradient (HVPG) decreases in most patients who have an SVR,¹⁸³ which could primarily be explained by a decline in intrahepatic vascular resistance. In contrast, data on the effect of SVR on portal blood flow velocity in cirrhosis are limited and conflicting. Although a small paired phase-contrast MRI study reported that portal blood flow velocity is unaffected by SVR,¹⁸⁴ a Doppler ultrasound-based study found an increase from 12.44 to 14.14 cm per s.¹⁸⁵ HCV cure ameliorates abnormalities in routine coagulation tests and laboratory biomarkers suggestive of hypercoagulability, possibly leading to a more stable haemostatic equilibrium.^{186,187} Finally, although HCV eradication has been shown to improve systemic endothelial dysfunction, this effect seemed to be less marked or even absent in patients with cirrhosis^{188–192} and it is still unknown if or how endothelial dysfunction in the portal and splanchnic veins is modified. Clinical observation showed that the risk of PVT is not abolished and does not seem to relevantly decrease in the first years following HCV cure.^{193,194} This apparent contradiction between pathophysiological and clinical data is probably explained by the modest magnitude of the changes mentioned above on Virchow's triad components. There is a knowledge gap about the effect of HBV suppression, abstinence from alcohol, and weight loss on PVT incidence. Although it seems likely that removal or suppression of the primary causal factor during long-term follow-up will reduce PVT risk, surveillance for PVT should be continued regardless of curing the underlying issue. Long-term studies are therefore needed to define the effect of aetiological therapies on PVT risk. Until this knowledge gap is filled, surveillance for PVT should be continued regardless of aetiological cure.

Variceal bleeding

In patients with PVT, HVPG is not accurate to estimate portosystemic gradient because of the presinusoidal block. However, clinical retrospective observations indirectly suggest that PVT aggravates portal hypertension in patients with cirrhosis. First, after variceal bleeding, PVT has been independently associated with inability to control bleeding, 14-day and 6-week rebleeding¹⁹⁵ and 6-week mortality.¹⁹⁶ In addition, PVT has been associated with a longer time to achieve eradication of varices in patients undergoing endoscopic band ligation.¹⁹⁷ However, the rebleeding rate is similar in patients with or without PVT (45% at 1 year) treated with endoscopic band ligation and propranolol.^{198,199}

These considerations do not translate into practical specificities since managing variceal bleeding in patients with cirrhosis and PVT does not differ from those without PVT.⁷⁷ The only difference might be that TIPS should be systematically considered in patients with cirrhosis, PVT, and variceal bleeding, as TIPS prevents the recurrence of variceal bleeding and ascites and

positively affects PVT by restoring portal blood flow.¹⁹⁸ Initial concerns about anticoagulation and variceal bleeding in patients with cirrhosis and PVT have been waived, as anticoagulation is even associated with lower rates of variceal bleeding.²⁰⁰ Moreover, once variceal bleeding occurs, anticoagulation is not associated with poorer outcomes.²⁰¹

Rationale for anticoagulation

Once diagnosed PVT can spontaneously regress in up to two-thirds of patients, which seems more frequent in those with partial than complete PVT and those for whom liver function improves.²⁰² By contrast, the rate of spontaneous recanalisation is very low in patients with occlusive PVT.¹⁷⁷ Anticoagulation in patients with cirrhosis and PVT was studied in a meta-analysis of predominantly retrospective studies. Anticoagulation resulted in higher (partial or complete) recanalisation (71% vs 42%), complete recanalisation (53% vs 33%), and less progression of PVT (9% vs 33%), without an increase in any bleeding episodes.²⁰⁰ Anticoagulation is most effective if started within 6 months of diagnosis of PVT.²⁰³ Anticoagulation has long been proposed mainly for those for whom liver transplantation was considered to facilitate porto-portal anastomosis.

A growing body of evidence indicates that the beneficial effect of long-term anticoagulation in patients with cirrhosis goes beyond its effect on PVT. The first evidence came from a randomised controlled trial in patients with Child-Pugh B7 to C10 cirrhosis that evaluated the efficacy of LMWH in preventing PVT.²⁰⁴ In this study, enoxaparin (40 mg subcutaneously daily) reduced incident PVT by 90% and death and hepatic decompensation by nearly 70%.²⁰⁴ Enoxaparin treatment, but not PVT, was independently associated with preventing decompensation and death. Similar results were found in a randomised controlled trial performed in 90 patients with Child-Pugh B7 to C10 cirrhosis.²⁰⁵ In this study, the incidence of portal hypertension-related complications (mostly ascites) was lower in patients who received rivaroxaban 10 mg per day than in those who received placebo, without an increase in major bleeding events. Next, in a well-matched cohort of US veterans with atrial fibrillation and cirrhosis (mostly Child-Pugh A), warfarin and direct oral anticoagulants were associated with lower all-cause mortality and hepatic decompensation compared with no anticoagulation.²⁰⁶ Finally, an individual participant data meta-analysis of five non-randomised studies containing 500 patients that compared anticoagulation with LMWH or vitamin K agonists with no anticoagulation in patients with cirrhosis and PVT. LMWH or vitamin K agonists improved overall survival after adjustment for confounders, including Child-Pugh score.²⁰⁷ The survival benefit of anticoagulation was independent of PVT recanalisation. However, it is worth noting that there was increased risk of portal hypertension unrelated bleeding

in patients receiving anticoagulation (9.7% vs 1.7%, $p < 0.001$). In agreement with this finding, aggregated data meta-analyses of anticoagulation in patients with cirrhosis and PVT also show that anticoagulation improves survival.^{208,209} An important conclusion drawn from these studies is that the beneficial effects of anticoagulation on cirrhosis progression is independent of the drug used.

Preclinical studies investigated the beneficial effect of anticoagulation in cirrhosis. Liver inflammation activates thrombin and protease-activated receptors, promoting hepatic stellate cell activation and thus supporting the hypothesis that anticoagulation could reduce fibrogenesis and cirrhosis progression. This hypothesis is supported by the following evidence: thrombin generation is maintained or increases throughout cirrhosis progression;²¹⁰ fibrogenesis is increased in mice with a mutation to factor V Leiden and CCl₄-induced cirrhosis and decreased in transgenic mice overexpressing tissue factor pathway inhibitor with inferior vena cava ligation;^{211,212} and chronic treatment with enoxaparin or rivaroxaban decreases collagen and fibrin deposition, deactivates hepatic stellate cells, and reduces portal pressure in different models of rats with cirrhosis.^{213,214} Proposed indications for anticoagulation are summarised in panel 2.

What type of anticoagulant?

The choice of anticoagulant is based on the type of thrombosis (recent vs chronic PVT), the context (mesenteric ischaemia, listing for liver transplantation, etc), and the patient, especially the severity of cirrhosis and comorbidities. The characteristics and limitations of the most used anticoagulants are summarised in the appendix (p 11).²¹⁵ In patients with recent thrombosis, especially those presenting with (or at risk of) mesenteric ischaemia, LMWH is preferred

Panel 2: Indications for anticoagulation in patients with cirrhosis and PVT

Non-candidates for liver transplantation

Usual indications

- Recent (<6 months) completely or partially occlusive (>50%) thrombosis of the main portal vein
- Symptomatic PVT (independent of the PVT extension)
- Progression of PVT without anticoagulation
- Extension to the superior mesenteric vein

Debated indications

- Minimally occlusive (<50%) thrombosis of the main portal vein

Potential candidates for liver transplantation

Usual indications

- Any PVT (independent of the degree of occlusion and extension)

PVT=portal vein thrombosis.

due to their short half-life and predictable pharmacokinetics. LMWH has been suggested to be more effective than warfarin concerning complete PVT resolution, although this has not been prospectively evaluated.²⁰⁰ The anti-Xa assay can lead to excessive dosing due to reduced antithrombin levels, especially in more advanced cirrhosis.²¹⁶ Fondaparinux has the advantage of once-fixed daily dosing with a reduced risk of heparin-induced thrombocytopenia, potentially higher efficacy than LMWH, but with an increased risk of bleeding (albeit minor).²¹⁷

For longer-term management, vitamin K agonists have historically been used in patients with cirrhosis and have the advantage of once-daily oral therapy. International normalised ratio (INR) monitoring can be challenging due to baseline elevated INR. A platelet count of less than 50×10^9 per L with a vitamin K antagonist is associated with an increased risk of bleeding.²¹⁸ An advantage of vitamin K agonists over direct oral anticoagulants or LMWH is the availability and familiarity with reversal agents. Thus, vitamin K agonists remain preferred for patients on the liver transplantation waiting list, provided the baseline INR is not substantially elevated. In most Western countries, it should be noted that donor allocation policy is based on the patient's MELD score. A pitfall of vitamin K agonists in candidates for transplantation is that the MELD score includes INR which is artificially increased by vitamin K antagonists, with a corresponding increase in MELD. Therefore, caution should be taken to avoid prioritising patients receiving vitamin K antagonists for organ allocation.

Patients with cirrhosis were systematically excluded from the seminal studies of direct oral anticoagulants in the management of venous thromboembolism and stroke prevention in atrial fibrillation. However, there has been much interest in the off-label use of direct oral anticoagulants in PVT, due to the ease of oral administration without the requirement for (INR) monitoring.^{219–223} Of note, direct oral anticoagulants also lead to an increase in INR, and thus could lead to the prioritising of patients on the waiting list for liver transplantation.²²⁴ The potential for direct oral anticoagulant accumulation in patients with decompensated cirrhosis remains a concern, although the metabolism of apixaban is not appreciably affected by chronic liver disease.²²⁵ However, available data from several meta-analyses suggest that the use of direct oral anticoagulants in patients with cirrhosis carry a risk of bleeding (including intracerebral haemorrhage or gastrointestinal) similar to or probably lower than vitamin K antagonists.^{203,226–228} In patients with cirrhosis, a 2023 meta-analysis of 29 studies showed that compared with conventional anticoagulants, direct oral anticoagulants were associated with lower incidences of all bleeding events (OR 0.71, 95% CI 0.52–0.98) and major bleeding events (OR 0.55, 95% CI 0.37–0.83), even in patients receiving direct oral anticoagulants for PVT.²²⁹ Small case

series report safe reversal of dabigatran in the peritransplant period.^{230,231} Therefore, there is a role for direct oral anticoagulants in Child-Pugh class A cirrhosis and with caution in Child-Pugh class B cirrhosis, but direct oral anticoagulants should generally be avoided in patients with Child-Pugh class C cirrhosis. Further prospective studies, including pharmacokinetic assays, are needed to optimise patient selection and choice of direct oral anticoagulants. Duration of anticoagulation remains uncertain, as 30–40% of the patients develop recurrent thrombosis between 2–5 months after cessation of anticoagulation.^{218,232,233}

Interventional radiology

Having previously been considered a contraindication to a TIPS procedure, PVT is increasingly seen as an indication. In candidates for liver transplantation, TIPS is an option to achieve recanalisation in patients with oblitative PVT and an alternative to anticoagulation in patients with partial PVT. The objectives are to recanalise the portal vein trunk and restore portal blood flow to allow end-to-end portal anastomosis during the transplant procedure. Even if TIPS is often effective at bridging patients with PVT to transplantation, this technique has some limitations. PVT is more common in patients with end-stage cirrhosis and a high MELD score. However, a high MELD score (>18) might represent a contraindication to TIPS due to the risk of further deterioration in liver function and a high rate of hepatic encephalopathy.^{234,235} In addition, misplacement of the TIPS can be a source of major technical difficulties during the transplant procedure, especially when the upper part of the stent is placed in the right atrium, or the lower part is placed in the mesenteric vein. For these reasons, stenting in PVT before transplantation should maintain 3–4 cm of unstented main portal vein, with the cranial end of the stent landing slightly short of the hepatic vein-caval confluence. In this patient population, stenting into the mesenteric system should never be performed. The second indication concerns patients with cirrhosis and PVT progressing despite anticoagulation when drug compliance is confirmed (eg, based on therapeutic drug monitoring) and HCC is excluded, even without a history of bleeding or ascites. No data are available to determine if TIPS is superior to anticoagulation in this context, and the choice between these two options should be discussed with expert centres.

The complexity of TIPS placement depends on the age of the thrombus, the degree of occlusion, and its extent (portal vein alone or involving additional splanchnic veins). The technical elements that allow a successful TIPS include the patency of intrahepatic portal branches,¹¹⁶ and a visible (even though occluded) portal vein on ultrasound when the clot is recent. However, there is an increase in reports of successful TIPS in patients with cavernoma, and no visible intrahepatic portal vein.²³⁶ In this setting, this approach uses a

transplenic or transjugular rendezvous approach that despite being technically challenging, is rapidly gaining adoption and use in multiple centres to permit socialisation of the procedure. It remains at the technically challenging end of the TIPS spectrum.

In patients without occlusive PVT, the technical success rate of TIPS is 75–98% leading to recanalisation in 84% of patients (including complete recanalisation in 73% of patients).²³⁷ After complete recanalisation, long-term patency is maintained so anticoagulation might not be required.^{237,238} In patients with occlusive PVT—even those with cavernous transformation or involvement of the superior mesenteric vein—several case series have reported that recanalisation can occur in 65–100% of cases.^{236,236,238,239} The overall complication rate in expert centres is around 10%, and is even higher following thrombectomy or thrombolysis.²³⁷

PVT and hepatocellular carcinoma

In patients with cirrhosis, HCC is a specific risk factor for tumoral portal vein obstruction and PVT. Differentiating tumoral portal vein obstruction from PVT is essential. The presence of more than three non-invasive A-VEHA criteria (comprising thrombus enhancement, enlargement of the portal vein, neo-vascularity, proximity to HCC or prior treatment site, and α -fetoprotein [AFP] greater than 1000 ng/dL), have 100% sensitivity, 93.6% specificity, 80% positive predictive value, and 100% negative predictive value for tumoral portal vein obstruction.²⁴⁰

In patients awaiting liver transplantation, the prevalence of PVT is higher in patients with HCC (41% vs 27%) than in those without.^{241–244} Two prospective studies showed that HCC is an independent risk factor for PVT, with a 1-year incidence of 25%, even in patients with compensated cirrhosis.^{245,246} Patients particularly at risk are those with multinodular HCC, a total tumour volume greater than 3 cm³, or both.^{245–247} This increased thrombotic risk in HCC could be explained by multiple prothrombotic alterations of haemostasis driven by HCC, illustrated by the increased maximum clot firmness at thromboelastography observed in patients with HCC and PVT.²⁴⁵ Mechanisms underlying this prothrombotic state include thrombocytosis (or a normal platelet count despite clinically significant portal hypertension), increased platelet activation and function, increased plasma fibrinogen, inhibition activation of fibrinolysis, higher levels of prothrombotic circulating microvesicles, and increased neutrophil extracellular traps and contact activation system.²⁴⁸

The natural history of PVT in patients with HCC and its effect on mortality has not yet been investigated. Only one single-centre study explored the evolution of PVT in patients with HCC. In 75 patients not receiving anticoagulation, PVT progressed in 63%, improved in 7%, and remained stable in 30%.²⁴⁹ Progression of PVT was associated with non-response to HCC treatment. Of

27 patients receiving anticoagulation, more than 50% had an improvement in PVT, while only 7% had progression.²⁴⁹ The presence of PVT complicates HCC treatment by increasing the morbidity and mortality of hepatic resection and complicating trans-arterial chemoembolisation. Accordingly, when PVT is complete or progressive, HCC and liver-related mortality is increased.²⁴⁹

In patients with HCC without PVT, the question of using prophylaxis to prevent PVT is unanswered. The number needed to treat to prevent one PVT with anticoagulation is about 6.⁶ Although waiting for dedicated prospective studies, anticoagulation could be considered to prevent PVT in patients with large tumour burden and concomitant portal hypertension. Anticoagulation should also be considered in patients with partial PVT and not delayed until progression since it seems to affect prognosis. Since response to anticoagulation seems lower in patients with PVT and HCC than in those with PVT without HCC,²⁴⁹ full-dose anticoagulation should be considered as soon as PVT occurs in patients with HCC. LMWH remains the standard treatment for cancer-associated thrombosis in patients without cirrhosis, and LMWH has been shown to be superior to vitamin K antagonists in terms of efficacy and safety in many clinical trials.²⁵⁰ Caution must be used in patients treated with tyrosine kinase inhibitors since these drugs interfere with direct oral anticoagulants and LMWH.^{251,252} Dose adjustment might be needed.²⁵³

PVT and liver transplantation

Detailed imaging using CT or MRI should be systematic during the evaluation process for eligibility for liver transplantation, with special attention given to portal and mesenteric vein patency. In addition, due to the 5–10% chance of new PVT occurring after registration on the waiting list for liver transplantation, periodic screening with Doppler ultrasound is strongly recommended for all patients awaiting transplantation.

During transplantation, one key challenge is restoring portal blood flow to decrease the risk of delayed graft function and prevent post-transplant thrombosis.²⁵⁴ Every technical effort should be made to avoid stricture and excessive length of the anastomosed veins. However, a pre-existing PVT remains one of the main risk factors for post-operative complications. The intraoperative strategy should be defined based on carefully assessing the pre-transplantation images of the thrombus and the portosystemic collaterals.²⁵⁵ A physiological liver blood inflow draining the mesentery should be restored whenever possible. In patients with PVT affecting only part of the spleno-mesenteric veins (Yerdel 1–3), strategies include thrombectomy, jump graft from the mesenteric vein, reno-portal anastomosis, or anastomosis between a large varix and the donor portal vein.^{255–257} Procedures not respecting the physiological portal inflow (typically

Panel 3: Consensus recommendations for endpoints for studies on portal vein thrombosis

Classification of PVT extension

- For studies on the natural history or medical treatment of PVT, the classification proposed in the AASLD and Baveno VII guidelines should be used (degree of agreement 96%).
- For studies related to liver transplantation, Yerdel's classification should be used (degree of agreement 80%).
- For studies on interventional radiology (including portal vein recanalisation, TIPS), Marot's classification should be used (degree of agreement 77%).

Classification of PVT evolution

- Measurement of the degree of occlusion of PVT should be assessed on contrast-enhanced cross-sectional imaging with the portal venous phase on a plane strictly perpendicular to the main portal vein (degree of agreement 96%).
- Minimal thrombosis or occlusion corresponds to a %RL equal to or greater than 50%, partial thrombosis or occlusion corresponds to a %RL less than 50%, and complete thrombosis or occlusion corresponds to a %RL of 0% (degree of agreement 96%).
- Upstream and downstream veins, namely the superior mesenteric vein, splenic vein, and right and left portal branches should be visually assessed using a semi-quantitative scale, as follows: no thrombosis=no thrombus or occlusion; incomplete thrombosis=any amount of thrombus or occlusion but visible remnant lumen; complete thrombosis=no remnant lumen (degree of agreement 94%).
- The VALDIG PVT criteria evaluating PVT evolution should be based on changes in the three following criteria: thrombus of the main portal vein, thrombus of the upstream and downstream veins, and occurrence of new thrombus in veins initially devoid of thrombus. These criteria allow the categorisation of PVT into four categories: complete resolution, improvement, stability, and progression of PVT (degree of agreement 93%).

Timing of assessment

- For patients in a stable clinical condition endpoints should be assessed on imaging at 6 and 12 months (degree of agreement 88%).
- For patients at particularly high risk of recurrent PVT or progressive PVT (eg, patients on the orthotopic liver transplant waiting list who cannot receive anticoagulation) endpoints should be assessed on imaging at 4–6 weeks intervals (degree of agreement 85%).
- For patients with worsening signs of portal hypertension or liver function, endpoints should be assessed immediately, to identify progression and proceed to TIPS or other treatment options (degree of agreement 98%).

Global endpoints for studies on PVT

- Global endpoints for studies on PVT should be different for patients with PVT in the absence versus in the presence of cirrhosis as well as for those patients with recent versus chronic PVT (degree of agreement 98%).

AASLD=American Association for the Study of the Liver. PVT=portal vein thrombosis. TIPS=transjugular intrahepatic portosystemic shunt. %RL=percentage of the remnant lumen.

reno-portal anastomosis in the absence of a splenorenal shunt or a cavoportal anastomosis) are associated with poorer post-transplant outcomes.^{256,258} In patients with diffuse spleno-mesenteric thrombosis (Yerdel 4) and no dominant collateral shunting, the risk to benefit profile should be carefully balanced. Pretransplant portal vein recanalisation, a non-physiological cavo-portal anastomosis, or a multivisceral transplantation can be

considered in some patients. The need for postoperative anticoagulation remains debated,^{259,260} and should be defined together with the surgeon, who can best appreciate the quality of the portal inflow. Long-term anticoagulation can be advised in patients with a hypercoagulable state, non-physiological portal vein reconstruction (or both), or interposition graft.²⁵⁵

Endpoint for clinical studies on PVT

Classification of PVT extension

The heterogeneity of PVT location, extent, and degree of occlusion calls for standardised descriptive terminology to improve the reporting, comparison, and validation of future studies and trials. Many classifications have been proposed to date that take into consideration various anatomical landmarks, various degrees of occlusion, and the coexistence of collaterals or an underlying hepatic disease. The main published PVT classification systems are summarised in the appendix (p 14). This section details the results of the Delphi expert consensus process, which aimed to determine optimal endpoints for clinical studies of PVT (appendix p 31–34).

Several classifications differentiate the involvement of segmental intrahepatic branches, left and right portal vein branches, and the main portal vein. Some also include a possible extension to portal vein tributaries, such as the splenic and superior mesenteric veins. The 2021 practice guidelines from the American Association for the Study of Liver Diseases (AASLD) suggest using three categories: intrahepatic, main portal vein, and portal vein tributaries,²¹⁵ but neither the recent update from the Baveno consensus⁷⁷ nor the Chinese guidelines²⁶¹ on PVT in cirrhosis mention any anatomical classification. The assessment of the residual portal venous lumen is also essential. Although some studies differentiate complete from partial occlusion, others favour using thresholds. For instance, the Baveno group, in line with Yerdel and colleagues,²⁵⁶ recommends separating complete occlusions (no persistent lumen) from partially occlusive thrombosis (obstructing more than 50% of the original vessel lumen) and minimally occlusive thrombosis (obstructing less than 50% of the original vessel lumen).⁷ More granular systems exist, such as the one proposed by Bauer and colleagues²⁶² in patients undergoing TIPS and endovascular procedures. Although no consensual definition exists, the presence of cavernoma should be reported. Finally, the length of thrombosis or the clot burden could represent promising endpoints similar to what has been validated in brain ischaemia or pulmonary embolism.²⁶³ Dedicated technologies are needed to translate this into clinical practice.

Most classifications were developed in patients undergoing liver transplantation and focused on short-term clinical outcomes. A few studies have assessed the relationship between the location of PVT and clinical outcomes in patients with cirrhosis who were not candidates for liver transplantation,^{262,264} or for patients

with PVT in the absence of cirrhosis undergoing endovascular portal vein recanalisation,⁸⁸ but long-term outcome data are scarce. Onda and colleagues²⁶⁵ also proposed a classification of PVT occurring after hepatic resection according to the site and grade of the thrombus. In another context, several classifications of portal vein tumour invasion have been published. Although they do not deal with the same patients, they are worth mentioning because they propose to label the different sites of portal vein occlusion, which facilitates the comparison between studies. The Vp classification system from the Japan Liver Cancer Study Group is the most commonly used.²⁶⁶ The occlusions are classified from Vp1 (thrombus located beyond second-order branches) to Vp4 (thrombus located in the main portal vein),²⁶⁶ which can also be applied to patients with PVT without tumour invasion.

Accordingly, the classifications of PVT extension depend on the clinical situation (appendix p 30). For studies on the natural history or medical treatment of PVT, the classification proposed in the AASLD²¹⁵ and Baveno VII guidelines⁷⁷ should be used (panel 3, degree of agreement 96%). For studies related to liver transplantation, Yerdel's classification²⁵⁶ should be used (panel 3, degree of agreement 80%). For studies on interventional radiology (including portal vein recanalisation, TIPS), Marot's classification⁸⁸ should be used (panel 3, degree of agreement 77%).

Classification of PVT evolution

Evolution of PVT encompasses the occurrence of PVT in a patient without previous PVT, or recanalisation or extension of PVT in a patient with previous PVT. There are many unanswered questions regarding clot surveillance and techniques for monitoring therapeutic efficacy in

patients with PVT. Although contrast-enhanced CT and MRI are the recommended imaging techniques, no head-to-head comparison exists to determine the best one. Studies that categorise the progression of PVT as either part of the natural history or as a response to treatment rarely assess the volume or anatomical location of the clot nor the clinical consequences of such progression.²⁰⁰ The criteria used in clinical trials or proposed in guidelines²⁶¹ to classify PVT evolution are summarised in appendix (p 19).

We thus decided to conduct a pilot study including 44 patients with PVT (32 with cirrhosis and 10 with portosinusoidal vascular disorder) to determine the reproducibility of assessment of PVT.²⁶⁷ We found that the remnant lumen, as a percentage of remnant portal lumen largest diameter (%RL), was the most reproducible feature (ie, better intraclass correlation coefficient, better Pearson correlation coefficient, narrower limit of agreement on the Bland Altman plot). We also found that the limits of agreement of %RL were plus or minus 22%; therefore, we proposed to round this to 25% for convenience. These results allowed us to propose standardised criteria to categorise main portal vein thrombus, and its progression (decrease of more than 25% of the %RL) or improvement (increase of more than 25% of the %RL). These criteria are summarised in table 1 and figure 2.

Based on these findings, we proposed the following statements, each reported by the degree of agreement. Measurement of the degree of occlusion of PVT should be assessed on contrast-enhanced cross-sectional imaging with the portal venous phase on a plane strictly perpendicular to the main portal vein (panel 3, degree of agreement 96%).

Studies on PVT should focus on the patency of the main portal vein, given its frequent involvement and that

Main portal vein thrombus	Thrombus of the upstream and downstream veins*	New thrombus site	Overall assessment	Degree of agreement
Complete resolution†	Complete resolution†	No	Complete resolution	97%
Complete resolution†	No complete resolution or no unequivocal progression‡	No	Improvement	98%
Complete occlusion that becomes partial; increase by more than 25% of the %RL§	Complete resolution; no unequivocal progression‡	No	Improvement	94%
Increase or decrease of 25% or less of the %RL§	No complete resolution or no unequivocal progression‡	No	Stability	96%
Partial occlusion becoming complete; decrease by more than 25% of the %RL§	Any	Any	Progression	96%
Any	Unequivocal progression‡ of one or more thrombosis site	Any	Progression	96%
Any	Any	Yes	Progression	93%

The proposed criteria follow the structure of the RECIST criteria used in oncology.²⁶⁸ The core concepts are: to assess the thrombus of the main portal vein following the methodology presented; to assess the thrombus of the upstream and downstream veins following the methodology presented above; to assess the occurrence of new thrombus in veins initially free from thrombus; and to combine the above assessments in order to categorize the patients into four categories: complete resolution, improvement, stability, and progression of the thrombus. *Upstream veins refer to splenic vein, superior mesenteric vein, and inferior mesenteric vein. Downstream vein refers to right and left portal branches. †Complete disappearance of any thrombus in the considered vein. Synonym of complete recanalisation. ‡Unequivocal decrease of the remnant lumen in the considered vein. This feature is visually assessed. Equivocal progressions should be considered as non-progression. §%RL, percentage of the remnant lumen according to the described methodology.

Table 1: The VALDIG PVT criteria

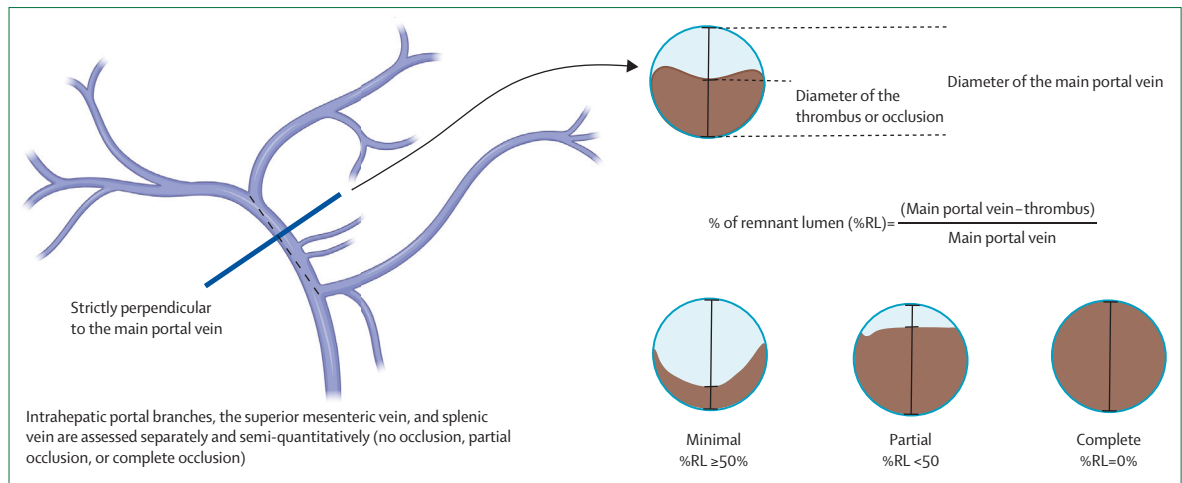


Figure 2: Methods to be used to assess portal vein thrombus on CT scan

For the portal vein: measurements are to be performed on a plane strictly perpendicular to the main portal vein on portal venous phase cross-sectional imaging; select the image visually displaying the smaller remnant portal vein lumen; take measurement of the largest diameter of the main portal vein of this image (mm); take measurement of the largest thrombus on the same image (mm). Compute the percentage of remnant lumen of the main portal vein (%RL), further categorised as: minimal thrombus (%RL $\geq 50\%$), partial thrombus (%RL $< 50\%$), and complete thrombus (%RL = 0%). Ideally, the same imaging modality should be used to monitor the evolution of the thrombus. For up and downstream veins the superior mesenteric vein, splenic vein, and right and left branches are visually assessed using a semiquantitative scale: no thrombosis (no thrombus, complete patency), incomplete thrombus (any amount of thrombus but visible remnant lumen), and complete thrombus (no remnant lumen).

it has the most tangible haemodynamic and clinical consequences. Measurements should be performed after selecting the image visually displaying the smallest remnant portal vein lumen and include: the measurement of the largest diameter of the main portal vein on this image (mm), and the measurement of the largest thrombus on the same image (mm), in order to compute the percentage of remnant portal lumen (%RL; figure 2). Minimal thrombosis or occlusion corresponds to a %RL equal to or greater than 50%, partial thrombosis or occlusion corresponds to a %RL less than 50%, and complete thrombosis or occlusion corresponds to a %RL of 0% (panel 3, degree of agreement 96%).

Upstream and downstream veins, namely the superior mesenteric vein, splenic vein, and right and left portal branches should be visually assessed using a semi-quantitative scale, as follows: no thrombosis: no thrombus or occlusion; incomplete thrombosis: any amount of thrombus or occlusion but visible remnant lumen; complete thrombosis: no remnant lumen (panel 3, degree of agreement 94%).

The VALDIG PVT criteria evaluating PVT evolution should be based on changes in the three following criteria: thrombus of the main portal vein, thrombus of the upstream and downstream veins, and occurrence of new thrombus in veins initially devoid of thrombus. These criteria allow for the categorisation of the PVT into four categories: complete resolution, improvement, stability, and progression of PVT (table 1, panel 3; degree of agreement 93%).

Future clinical trials should strive to standardise and quantify clot volume and treatment responses, specifically using modern imaging technologies such as

3D portal vein reconstruction, clot volume quantification, or both, and set thresholds for changes in clot volume that should be considered clinically relevant. Examples of this technology as applied to PVT are published elsewhere.^{269,270} Crucially, establishing a correlation between thrombus-based surrogate markers and validated clinical endpoints is needed to guide clinicians on the relevance of interventions in PVT for improved clinical outcomes in affected patients.

Timing of assessment

In the context of PVT, repeated standardised imaging should: inform the progression or spontaneous regression of thrombosis in patients in whom a watchful waiting approach in the context of cirrhosis has been chosen; inform the response to anticoagulation (improvement, stability, progression of PVT); and provide anatomical details to select an appropriate treatment in case of complications (eg, variceal bleeding). Imaging protocols should be guided by safety and reliability. High-quality data regarding the optimal timing for assessment of PVT evolution in patients with PVT with or without cirrhosis are lacking, and data are mainly derived from systematic reviews of retrospective data and expert opinion (figure 3).⁷⁷

PVT with cirrhosis

In patients with minimally occlusive PVT (<50%) not undergoing anticoagulation, ultrasound is usually sufficient to identify progression or regression.¹⁶⁹ Follow-up ultrasound every 4–6 weeks in the first 3 months and subsequently every 3 months within the first year might be proposed. Follow-up with contrast-enhanced imaging might be considered after 6 months. Patients not

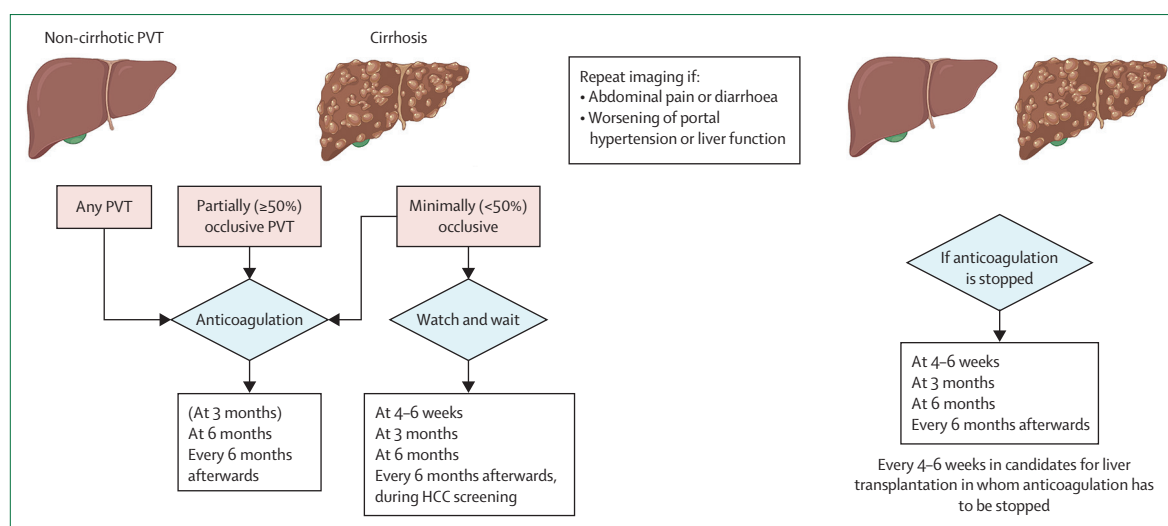


Figure 3: Timing of assessment in studies on PVT in patients with and without cirrhosis

After the diagnosis of recent PVT, imaging should be repeated at 6 months (with contrast-enhanced CT) and 12 months for patients in good clinical conditions, with an additional control at 3 months commonly performed. In patients with PVT treated with anticoagulation, a control should be performed at 6 and 12 months after starting treatment if the patient is stable. Additional imaging is commonly planned 3 months after treatment to analyse early response to anticoagulation. If a decision to stop anticoagulation is taken, imaging controls every 3 months (every 4–6 weeks on the waiting list for liver transplantation) seem reasonable. In case of clinical worsening, imaging should be repeated irrespective of the timing. PVT=portal vein thrombosis

progressing after 12 months might be kept under standard imaging surveillance every 6 months.

In patients with PVT in whom anticoagulation has been decided, follow-up imaging should be performed 6 and 12 months after starting treatment if the patient is in a stable condition. Additional control is commonly planned 3 months after treatment to depict early response to anticoagulation. In patients with worsening clinical condition (eg, worsening ascites) who are potentially candidates for TIPS, imaging should be repeated irrespective of the timing mentioned to identify (or exclude) thrombosis progression to the superior mesenteric vein and splenic vein. If a decision to stop anticoagulation is taken, thrombosis recurrence might occur in the first 2–5 months. Hence, imaging follow-up every 3 months seem reasonable. In patients on the waiting list for liver transplantation, given the importance of recurrent PVT in this setting, the interval can be reduced to every 4–6 weeks.

PVT without cirrhosis

The proposed timing does not differ from that suggested for PVT in cirrhosis. Namely, after the diagnosis of recent PVT, imaging should be repeated at 6 months (with contrast-enhanced CT) and 12 months for patients in good clinical condition, with an additional control at 3 months commonly performed.⁷ In case of clinical worsening, imaging should be repeated irrespective of the timing. For patients with a chronic PVT with cavernous transformation, the 12-month CT control might coincide with an assessment of portal cholangiopathy using magnetic resonance cholangiography. In patients who improved or are stable on treatment, an ultrasound every

6–12 months and a contrast-enhanced CT or MRI every 2–4 years seem reasonable.⁸¹

To summarise, results of the Delphi consensus indicated that both for patients with and without cirrhosis, endpoints for clinical studies on PVT should be assessed at imaging: for patients in a stable clinical condition: at 6 months and 12 months (panel 3, degree of agreement 88%); for patients at particularly high risk of recurrent PVT or progressive PVT (eg, patients on the orthotopic liver transplant waiting list who cannot receive anticoagulation): at 4–6 weeks intervals (panel 3, degree of agreement 85%); and for patients with worsening of signs of portal hypertension or liver function: immediately, to identify progression and proceed to TIPS or other treatment options (panel 3, degree of agreement 98%).

Global endpoints for studies on PVT

In patients with PVT in the absence of cirrhosis, the main objective is to prevent the extension of the thrombus to the superior mesenteric vein and, accordingly, prevent intestinal ischaemia.²⁷¹ After PVT occurrence, portal recanalisation is the most important thrombus-related outcome. Clinical complications, namely portal hypertension and portal cholangiopathy, do not occur in patients who have recanalisation.²⁷¹ However, recanalisation cannot be the only outcome of interest. First, recanalisation only occurs in around 30–40% of patients with recent PVT in the absence of cirrhosis treated with anticoagulation.^{5,82} Second, after recanalisation, there is an 18–38% risk of recurrent thrombosis.^{80,272,273} Third, patients with PVT in the absence of cirrhosis are at an increased risk of developing other

	Thrombus outcome	Degree of agreement	Clinical events	Degree of agreement
Recent PVT in the absence of cirrhosis	Avoid progression and ideally promote thrombus regression and prevent extra-splanchnic venous thrombosis	93%	Portal hypertension related events; mesenteric ischaemia; major bleeding not caused by portal hypertension (ie, safety of anticoagulation)	93%
Chronic PVT in the absence of cirrhosis	Avoid progression and prevent extra-splanchnic venous thrombosis	96%	Portal hypertension related events; mesenteric ischaemia; portal cholangiopathy complications; health-related quality of life; major bleeding not caused by portal hypertension (ie, safety of anticoagulation)	95%
Recent PVT in patients with cirrhosis	Avoid progression and ideally promote thrombus regression and enable a physiological portal anastomosis at time of liver transplant surgery in current or future liver transplant candidates	96%	Decompensation of cirrhosis; mesenteric ischaemia; major bleeding not caused by portal hypertension (ie, safety of anticoagulation)	95%
Chronic PVT in patients with cirrhosis	Avoid progression and ideally promote thrombus regression. Enable a physiological portal anastomosis at time of liver transplant surgery in current or future liver transplant candidates	96%	Decompensation of cirrhosis; major bleeding not caused by portal hypertension (ie, safety of anticoagulation); post-transplant mortality and graft failure; health-related quality of life	95%

PVT=portal vein thrombosis.

Table 2: Relevant endpoints for clinical studies on PVT

extrasplanchnic venous thrombosis regardless of portal recanalisation, especially in those with a strong risk factor for thrombosis recurrence.⁸⁰

In patients with cirrhosis and PVT, the main objective of treating PVT is to recanalise the portal vein trunk and restore portal blood flow to allow end-to-end portal anastomosis during the transplantation procedure, and therefore prevent postoperative complications and early graft failure.²⁵⁸ As PVT aggravates portal hypertension, another objective would be to decrease the incidence of decompensation of cirrhosis, and consequently transplant-free survival. However, whether recanalisation directly influences liver-related outcomes has not been shown.²⁰⁷

For studies involving patients with PVT, we believe that clinical endpoints should be: clinically relevant; associated with thrombus regression or progression; meaningful to the patient; and take into account the safety of the treatment. Certainly, survival is another relevant clinical outcome that can be considered in clinical studies on PVT in the absence of cirrhosis; however, due to the very low mortality rate, powering studies based solely on this outcome alone is not feasible.

Search strategy and selection criteria

References for this Review were identified through PubMed searches using the search terms “recent portal vein thrombosis”, “chronic portal vein thrombosis”, “portal cavernoma”, “extra-hepatic portal vein obstruction”, and “portal vein thrombosis and cirrhosis” from database inception until Dec 31, 2023. Articles were also identified through searches of the authors’ own files. Only papers published in English and French were reviewed. The final reference list was generated based on originality and relevance to the scope of this Review.

To summarise, global endpoints for studies on PVT should be different for patients with PVT in the absence versus in the presence of cirrhosis as well as for those patients with recent versus chronic PVT (panel 3, degree of agreement 98%). Similarly, global endpoints for studies on PVT can focus on the thrombus outcome, on clinical events, or both (table 2).

Conclusion

The growing interest in PVT within the medical community has led to substantial advances in knowledge, primarily through observational studies. These studies have shown a correlation between PVT and an elevated risk of complications related to portal hypertension, both in patients with and without cirrhosis. Currently, anticoagulation stands as the first-line treatment, with an increasing trend toward portal vein recanalisation using interventional radiology. However, the heterogeneous nature of existing studies hampers the development of standardised management of patients with PVT. In the coming years, randomised controlled trials are expected to provide clarity on the role of anticoagulation and interventional radiology in PVT management. These studies will necessitate differentiation between patients with cirrhosis and those without, considering thrombus outcomes and relevant clinical events. Lastly, future clinical trials should assess the interest of quantifying the degree of obstruction and use contemporary imaging technology to refine the evaluation of the degree of obstruction and treatment responses.

Contributors

Conceptualisation of the manuscript: LE, PER. Data curation and analysis of original data in the pilot study: LE, LM, VP, MR. All authors contributed to the writing, review, and editing of the initial draft.

Acknowledgments

The Paris PVT meeting was supported by FILFOIE, ERN-RARE Liver, Société Nationale Française de Gastroentérologie, and Association

Française pour l'étude du Foie. This Review was written on behalf of the ERN RARE-LIVER group, and was a study supported by VALDIG, an EASL consortium.

Declaration of interests

VHG has received speaker fees from Gore Medical and Cook Medical. ADG has received consulting fees from AstraZeneca and Swedish Orphan Biovitrum. MR serves as consultant from Quantum Surgical (fees paid to institution) and has received speaker fees from Servier, Guerbet, GE Healthcare, Ipsen, Angiodynamics, and AstraZeneca. FN has received speaker fees from Advanz and Permanyer. VML serves as consultant from AstraZeneca and has received speaker fees and travel support from Albireo Ipsen. AB serves as consultant for Boehringer Ingelheim and has received speaker fees from GE Healthcare and Hologic. AA has served as a lecturer for Boehringer-Ingelheim and Gore Medical. AN has received research funding from MSD-Avenir and consulting fees from Abbvie and Janssen. MM serves as a lecturer for Abbvie, Ipsen, Echosens, Gilead Sciences, and Gore Medical, and has received travel support from Abbvie and Gilead Sciences. DP has served as lecturer for Boehringer-Ingelheim and Gore Medical. DT has received research grants from Boehringer-Ingelheim and Novartis and has served as lecturer for Gore Medical. JCGP has received speaker fees from Gore Medical and research grants from Mallinkrodt and AstraZeneca. All other authors declare no competing interests.

References

- Berzigotti A, García-Criado A, Darnell A, García-Pagán J-C. Imaging in clinical decision-making for portal vein thrombosis. *Nat Rev Gastroenterol Hepatol* 2014; **11**: 308–16.
- De Gaetano AM, Lafortune M, Patriquin H, De Franco A, Aubin B, Paradis K. Cavernous transformation of the portal vein: patterns of intrahepatic and splanchnic collateral circulation detected with Doppler sonography. *AJR Am J Roentgenol* 1995; **165**: 1151–55.
- Jha RC, Khera SS, Kalaria AD. Portal vein thrombosis: imaging the spectrum of disease with an emphasis on MRI features. *AJR Am J Roentgenol* 2018; **211**: 14–24.
- Copin P, Ronot M, Nuzzo A, et al. Inter-reader agreement of CT features of acute mesenteric ischemia. *Eur J Radiol* 2018; **105**: 87–95.
- Plessier A, Darwish-Murad S, Hernandez-Guerra M, et al. Acute portal vein thrombosis unrelated to cirrhosis: a prospective multicenter follow-up study. *Hepatology* 2010; **51**: 210–18.
- Senzolo M, Garcia-Tsao G, García-Pagán JC. Current knowledge and management of portal vein thrombosis in cirrhosis. *J Hepatol* 2021; **75**: 442–53.
- Carneiro C, Brito J, Bilreiro C, et al. All about portal vein: a pictorial display to anatomy, variants and physiopathology. *Insights Imaging* 2019; **10**: 38.
- Vink CS, Mariani SA, Dzierzak E. Embryonic origins of the hematopoietic system: hierarchies and heterogeneity. *HemaSphere* 2022; **6**: e737.
- Su T, Yang Y, Lai S, et al. Single-cell transcriptomics reveals zone-specific alterations of liver sinusoidal endothelial cells in cirrhosis. *Cell Mol Gastroenterol Hepatol* 2021; **11**: 1139–61.
- Zhang H, Ma Y, Cheng X, et al. Targeting epigenetically maladapted vascular niche alleviates liver fibrosis in nonalcoholic steatohepatitis. *Sci Transl Med* 2021; **13**: eabd1206.
- Bondareva O, Rodríguez-Aguilera JR, Oliveira F, et al. Single-cell profiling of vascular endothelial cells reveals progressive organ-specific vulnerabilities during obesity. *Nat Metab* 2022; **4**: 1591–610.
- Trimm E, Red-Horse K. Vascular endothelial cell development and diversity. *Nat Rev Cardiol* 2023; **20**: 197–210.
- Wilson JB. Changes in the portal and splenic veins in portal hypertension and their relation to splenomegaly. *Gut* 1961; **2**: 310–15.
- Malmqvist U, Arner A. Isoform distribution and tissue contents of contractile and cytoskeletal proteins in hypertrophied smooth muscle from rat portal vein. *Circ Res* 1990; **66**: 832–45.
- Albinsson S, Nordström I, Hellstrand P. Stretch of the vascular wall induces smooth muscle differentiation by promoting actin polymerization. *J Biol Chem* 2004; **279**: 34849–55.
- Driever EG, von Meijenföldt FA, Adelmeijer J, et al. Nonmalignant portal vein thrombi in patients with cirrhosis consist of intimal fibrosis with or without a fibrin-rich thrombus. *Hepatology* 2022; **75**: 898–911.
- Lisman T, Porte RJ. Pathogenesis, prevention, and management of bleeding and thrombosis in patients with liver diseases. *Res Pract Thromb Haemost* 2017; **1**: 150–61.
- Violi F, Pignatelli P, Castellani V, Carnevale R, Cammisotto V. Gut dysbiosis, endotoxemia and clotting activation: a dangerous trio for portal vein thrombosis in cirrhosis. *Blood Rev* 2023; **57**: 100998.
- Praktiknjo M, Trebicka J, Carnevale R, et al. Von Willebrand and Factor VIII portosystemic circulation gradient in cirrhosis: implications for portal vein thrombosis. *Clin Transl Gastroenterol* 2020; **11**: e00123.
- Violi F, Ferro D, Basili S, et al. Ongoing prothrombotic state in the portal circulation of cirrhotic patients. *Thromb Haemost* 1997; **77**: 44–47.
- Delahousse B, Labat-Debelleix V, Decalonne L, d'Alteroche L, Perarnau J-M, Gruel Y. Comparative study of coagulation and thrombin generation in the portal and jugular plasma of patients with cirrhosis. *Thromb Haemost* 2010; **104**: 741–49.
- Queck A, Carnevale R, Uschner FE, et al. Role of portal venous platelet activation in patients with decompensated cirrhosis and TIPS. *Gut* 2020; **69**: 1535–36.
- Driever EG, Magaz M, Adelmeijer J, et al. The portal vein in patients with cirrhosis is not an excessively inflammatory or hypercoagulable vascular bed, a prospective cohort study. *J Thromb Haemost* 2022; **20**: 2075–82.
- Rahr HB, Sørensen JV, Larsen JF, Jensen FS, Bredahl C. Markers of coagulation and fibrinolysis in portal blood from patients with and without gastric malignancy. *Scand J Gastroenterol* 1994; **29**: 516–21.
- Violi F, Carnevale R, Pignatelli P. "The portal vein in patients with cirrhosis is not an excessively inflammatory or hypercoagulable vascular bed, a prospective cohort study": comment from Violi et al. *J Thromb Haemost* 2023; **21**: 186–87.
- Turon F, Driever EG, Baiges A, et al. Predicting portal thrombosis in cirrhosis: a prospective study of clinical, ultrasonographic and hemostatic factors. *J Hepatol* 2021; **75**: 1367–76.
- Hernández-Gea V, De Gottardi A, Leebeek FWG, Rautou P-E, Salem R, Garcia-Pagan JC. Current knowledge in pathophysiology and management of Budd-Chiari syndrome and non-cirrhotic non-tumoral splanchnic vein thrombosis. *J Hepatol* 2019; **71**: 175–99.
- Bureau C, Laurent J, Robic MA, et al. Central obesity is associated with non-cirrhotic portal vein thrombosis. *J Hepatol* 2016; **64**: 427–32.
- Zheng X, Gao F, Wang L, Meng Y, Ageno W, Qi X. Incidence and outcomes of splanchnic vein thrombosis after diagnosis of COVID-19 or COVID-19 vaccination: a systematic review and meta-analysis. *J Thromb Thrombolysis* 2023; **55**: 18–31.
- Deltenre P, Payancé A, Elkrief L, et al. Splanchnic vein thrombosis associated with SARS-CoV-2 infection: a VALDIG case-control study. *JHEP Rep Innov Hepatol* 2023; **5**: 100894.
- Maan R, Lauw MN, China L, et al. Extensive splanchnic vein thrombosis after SARS-CoV-2 vaccination: a Vascular Liver Disease Group (VALDIG) initiative. *Hepatology* 2024; published online Feb 15. <https://doi.org/10.1097/HEP.0000000000000787>.
- De Broucker C, Plessier A, Ollivier-Hourmand I, et al. Multicenter study on recent portal venous system thrombosis associated with cytomegalovirus disease. *J Hepatol* 2022; **76**: 115–22.
- Khetarpal SA, Qamar A, Bick AG, et al. Clonal hematopoiesis of indeterminate potential reshapes age-related CVD: JACC review topic of the week. *J Am Coll Cardiol* 2019; **74**: 578–86.
- Guy A, Poisson J, James C. Pathogenesis of cardiovascular events in BCR-ABL1-negative myeloproliferative neoplasms. *Leukemia* 2021; **35**: 935–55.
- Hermange G, Rakotonirainy A, Bentriou M, et al. Inferring the initiation and development of myeloproliferative neoplasms. *Proc Natl Acad Sci USA* 2022; **119**: e2120374119.
- Debureaux P-E, Cassinat B, Soret-Dulphy J, et al. Molecular profiling and risk classification of patients with myeloproliferative neoplasms and splanchnic vein thromboses. *Blood Adv* 2020; **4**: 3708–15.
- Magaz M, Alvarez-Larrán A, Colomer D, et al. Next-generation sequencing in the diagnosis of non-cirrhotic splanchnic vein thrombosis. *J Hepatol* 2021; **74**: 89–95.
- Iwakiri Y, Trebicka J. Portal hypertension in cirrhosis: pathophysiological mechanisms and therapy. *JHEP Rep Innov Hepatol* 2021; **3**: 100316.

- 39 Albillos A, Colombato LA, Groszmann RJ. Vasodilatation and sodium retention in prehepatic portal hypertension. *Gastroenterology* 1992; **102**: 931–35.
- 40 Sikuler E, Kravetz D, Groszmann RJ. Evolution of portal hypertension and mechanisms involved in its maintenance in a rat model. *Am J Physiol* 1985; **248**: G618–25.
- 41 Lebrec D, Bataille C, Bercoff E, Valla D. Hemodynamic changes in patients with portal venous obstruction. *Hepatology* 1983; **3**: 550–53.
- 42 Braillon A, Moreau R, Hadengue A, Roulot D, Sayegh R, Lebrec D. Hyperkinetic circulatory syndrome in patients with presinusoidal portal hypertension. Effect of propranolol. *J Hepatol* 1989; **9**: 312–18.
- 43 Seijo S, Reverter E, Miquel R, et al. Role of hepatic vein catheterisation and transient elastography in the diagnosis of idiopathic portal hypertension. *Dig Liver Dis* 2012; **44**: 855–60.
- 44 Alvarado E, Garcia-Guix M, Mirabet S, Villanueva C. The relationship of hyperdynamic circulation and cardiodynamic states in cirrhosis. *J Hepatol* 2018; **69**: 746–47.
- 45 Feu F, Bordas JM, Luca A, et al. Reduction of variceal pressure by propranolol: comparison of the effects on portal pressure and azygos blood flow in patients with cirrhosis. *Hepatology* 1993; **18**: 1082–89.
- 46 Villanueva C, Albillos A, Genesca J, et al. Development of hyperdynamic circulation and response to β -blockers in compensated cirrhosis with portal hypertension. *Hepatology* 2016; **63**: 197–206.
- 47 Bañares R, Moitinho E, Piqueras B, et al. Carvedilol, a new nonselective beta-blocker with intrinsic anti-alpha-adrenergic activity, has a greater portal hypotensive effect than propranolol in patients with cirrhosis. *Hepatology* 1999; **30**: 79–83.
- 48 Sharma P, Mishra SR, Kumar M, Sharma BC, Sarin SK. Liver and spleen stiffness in patients with extrahepatic portal vein obstruction. *Radiology* 2012; **263**: 893–99.
- 49 Shen Y, Ma W, Hang Y, Liu L-L, Jiang W, Wu S-D. Clinical application of liver stiffness measurement in patients with cavernous transformation of portal vein. *Exp Ther Med* 2021; **21**: 442.
- 50 Madhusudhan KS, Kilambi R, Shalimar, et al. Measurement of splenic stiffness by 2D-shear wave elastography in patients with extrahepatic portal vein obstruction. *Br J Radiol* 2018; **91**: 20180401.
- 51 Chatelin S, Pop R, Giraudeau C, et al. Influence of portal vein occlusion on portal flow and liver elasticity in an animal model. *NMR Biomed* 2021; **34**: e4498.
- 52 Sharma P, Agarwal R, Dhawan S, et al. Transient elastography (fibroscan) in patients with non-cirrhotic portal fibrosis. *J Clin Exp Hepatol* 2017; **7**: 230–34.
- 53 Elkrief L, Lazareth M, Chevret S, et al. Liver stiffness by transient elastography to detect porto-sinusoidal vascular liver disease with portal hypertension. *Hepatology* 2021; **74**: 364–78.
- 54 Ito K, Mitchell DG, Siegelman ES. Cirrhosis: MR imaging features. *Magn Reson Imaging Clin N Am* 2002; **10**: 75–92.
- 55 Vilgrain V, Lagadec M, Ronot M. Pitfalls in liver imaging. *Radiology* 2016; **278**: 34–51.
- 56 Vilgrain V, Condat B, Bureau C, et al. Atrophy-hypertrophy complex in patients with cavernous transformation of the portal vein: CT evaluation. *Radiology* 2006; **241**: 149–55.
- 57 Gupta P, Kalra N, Gulati A, et al. Changes in liver morphology in patients with extrahepatic portal venous obstruction: a retrospective magnetic resonance imaging study. *Br J Radiol* 2019; **92**: 20180890.
- 58 De Gottardi A, Sempoux C, Berzigotti A. Porto-sinusoidal vascular disorder. *J Hepatol* 2022; **77**: 1124–35.
- 59 Glatard A-S, Hillaire S, d'Assignies G, et al. Obliterative portal venopathy: findings at CT imaging. *Radiology* 2012; **263**: 741–50.
- 60 Kang JH, Kim DH, Kim SY, et al. Porto-sinusoidal vascular disease with portal hypertension versus liver cirrhosis: differences in imaging features on CT and hepatobiliary contrast-enhanced MRI. *Abdom Radiol* 2021; **46**: 1891–903.
- 61 Lampichler K, Semmler G, Wöran K, et al. Imaging features facilitate diagnosis of porto-sinusoidal vascular disorder. *Eur Radiol* 2023; **33**: 1422–32.
- 62 Valainathan SR, Sartoris R, Elkrief L, et al. Contrast-enhanced CT and liver surface nodularity for the diagnosis of porto-sinusoidal vascular disorder: a case-control study. *Hepatology* 2022; **76**: 418–28.
- 63 Barbui T, Vannucchi AM, Finazzi G, et al. A reappraisal of the benefit-risk profile of hydroxyurea in polycythemia vera: a propensity-matched study. *Am J Hematol* 2017; **92**: 1131–36.
- 64 Fruchtman SM, Mack K, Kaplan ME, Peterson P, Berk PD, Wasserman LR. From efficacy to safety: a Polycythemia Vera Study group report on hydroxyurea in patients with polycythemia vera. *Semin Hematol* 1997; **34**: 17–23.
- 65 Marchioli R, Finazzi G, Specchia G, et al. Cardiovascular events and intensity of treatment in polycythemia vera. *N Engl J Med* 2013; **368**: 22–33.
- 66 Masciulli A, Ferrari A, Carobbio A, Ghirardi A, Barbui T. Ruxolitinib for the prevention of thrombosis in polycythemia vera: a systematic review and meta-analysis. *Blood Adv* 2020; **4**: 380–86.
- 67 Cortelazzo S, Finazzi G, Ruggeri M, et al. Hydroxyurea for patients with essential thrombocythemia and a high risk of thrombosis. *N Engl J Med* 1995; **332**: 1132–36.
- 68 Tremblay D, Kosiorek HE, Dueck AC, Hoffman R. Evaluation of therapeutic strategies to reduce the number of thrombotic events in patients with polycythemia vera and essential thrombocythemia. *Front Oncol* 2021; **10**: 636675.
- 69 De Stefano V, Rossi E, Carobbio A, et al. Hydroxyurea prevents arterial and late venous thrombotic recurrences in patients with myeloproliferative neoplasms but fails in the splanchic venous district. Pooled analysis of 1500 cases. *Blood Cancer J* 2018; **8**: 112.
- 70 Hamulyák EN, Daams JG, Leebeek FWG, et al. A systematic review of antithrombotic treatment of venous thromboembolism in patients with myeloproliferative neoplasms. *Blood Adv* 2021; **5**: 113–21.
- 71 Mascarenhas J, Kosiorek H, Prchal J, et al. A prospective evaluation of pegylated interferon alfa-2a therapy in patients with polycythemia vera and essential thrombocythemia with a prior splanchic vein thrombosis. *Leukemia* 2019; **33**: 2974–78.
- 72 Pieri L, Paoli C, Arena U, et al. Safety and efficacy of ruxolitinib in splanchic vein thrombosis associated with myeloproliferative neoplasms. *Am J Hematol* 2017; **92**: 187–95.
- 73 Plessier A, Esposito-Farèse M, Baiges A, et al. Paroxysmal nocturnal hemoglobinuria and vascular liver disease: eculizumab therapy decreases mortality and thrombotic complications. *Am J Hematol* 2022; **97**: 431–39.
- 74 Gala D, Newsome T, Roberson N, et al. Thromboembolic events in patients with inflammatory bowel disease: a comprehensive overview. *Diseases* 2022; **10**: 73.
- 75 Alibaz-Oner F, Karadeniz A, Yılmaz S, et al. Behçet disease with vascular involvement: effects of different therapeutic regimens on the incidence of new relapses. *Medicine* 2015; **94**: e494.
- 76 Desbois AC, Rautou PE, Biard L, et al. Behçet's disease in Budd-Chiari syndrome. *Orphanet J Rare Dis* 2014; **9**: 104.
- 77 de Franchis R, Bosch J, Garcia-Tsao G, Reiberger T, Ripoll C, Baveno V. II Faculty. Baveno VII—renewing consensus in portal hypertension. *J Hepatol* 2022; **76**: 959–74.
- 78 Randi ML, Tezza F, Scapin M, et al. Heparin-induced thrombocytopenia in patients with Philadelphia-negative myeloproliferative disorders and unusual splanchic or cerebral vein thrombosis. *Acta Haematol* 2010; **123**: 140–45.
- 79 Naymagon L, Tremblay D, Zubizarreta N, et al. The efficacy and safety of direct oral anticoagulants in noncirrhotic portal vein thrombosis. *Blood Adv* 2020; **4**: 655–66.
- 80 Plessier A, Gorla O, Cervoni JP, et al. Rivaroxaban prophylaxis in noncirrhotic portal vein thrombosis. *NEJM Evid* 2022; **1**: a2200104.
- 81 Baiges A, Procopet B, Silva-Junior G, et al. Incidence and factors predictive of recurrent thrombosis in people with non-cirrhotic portal vein thrombosis. *J Hepatol* 2023; **78**: 114–22.
- 82 Turnes J, García-Pagán JC, González M, et al. Portal hypertension-related complications after acute portal vein thrombosis: impact of early anticoagulation. *Clin Gastroenterol Hepatol* 2008; **6**: 1412–17.
- 83 Noronha Ferreira C, Seijo S, Plessier A, et al. Natural history and management of esophagogastric varices in chronic noncirrhotic, nontumoral portal vein thrombosis. *Hepatology* 2016; **63**: 1640–50.
- 84 Spaander MCW, Hoekstra J, Hansen BE, Van Buuren HR, Leebeek FWG, Janssen HLA. Anticoagulant therapy in patients with non-cirrhotic portal vein thrombosis: effect on new thrombotic events and gastrointestinal bleeding. *J Thromb Haemost* 2013; **11**: 452–59.
- 85 Lattanzi B, Gioia S, Di Cola S, et al. Prevalence and impact of sarcopenia in non-cirrhotic portal hypertension. *Liver Int* 2019; **39**: 1937–42.

- 86 Guillaume M, Christol C, Plessier A, et al. Bleeding risk of variceal band ligation in extrahepatic portal vein obstruction is not increased by oral anticoagulation. *Eur J Gastroenterol Hepatol* 2018; **30**: 563–68.
- 87 Artru F, Vietti-Viola N, Sempoux C, et al. Portal vein recanalisation alone to treat severe portal hypertension in non-cirrhotic patients with chronic extrahepatic portal vein obstruction. *JHEP Rep Innov Hepatol* 2022; **4**: 100511.
- 88 Marot A, Barbosa JV, Duran R, Deltenre P, Denys A. Percutaneous portal vein recanalization using self-expandable nitinol stents in patients with non-cirrhotic non-tumoral portal vein occlusion. *Diagn Interv Imaging* 2019; **100**: 147–56.
- 89 Fanelli F, Angeloni S, Salvatori FM, et al. Transjugular intrahepatic portosystemic shunt with expanded-polytetrafluoroethylene-covered stents in non-cirrhotic patients with portal cavernoma. *Dig Liver Dis* 2011; **43**: 78–84.
- 90 Knight GM, Clark J, Boike JR, et al. TIPS for adults without cirrhosis with chronic mesenteric venous thrombosis and EHPVO refractory to standard-of-care therapy. *Hepatology* 2021; **74**: 2735–44.
- 91 Wei B, Huang Z, Wu H, et al. Portal vein recanalization for noncirrhotic portal vein cavernous transformation: transjugular intrahepatic portosystemic shunt creation versus portal vein stent placement. *J Vasc Interv Radiol* 2023; **34**: 187–94.
- 92 Chandra R, Kapoor D, Tharakan A, Chaudhary A, Sarin SK. Portal biliopathy. *J Gastroenterol Hepatol* 2001; **16**: 1086–92.
- 93 Dilawari JB, Chawla YK. Pseudosclerosing cholangitis in extrahepatic portal venous obstruction. *Gut* 1992; **33**: 272–76.
- 94 Llop E, de Juan C, Seijo S, et al. Portal cholangiopathy: radiological classification and natural history. *Gut* 2011; **60**: 853–60.
- 95 Condat B, Vilgrain V, Asselah T, et al. Portal cavernoma-associated cholangiopathy: a clinical and MR cholangiography coupled with MR portography imaging study. *Hepatology* 2003; **37**: 1302–08.
- 96 Shukla A, Gupte A, Karvir V, Dhore P, Bhatia S. Long term outcomes of patients with significant biliary obstruction due to portal cavernoma cholangiopathy and extra-hepatic portal vein obstruction (EHPVO) with no shuntable veins. *J Clin Exp Hepatol* 2017; **7**: 328–33.
- 97 Bhatia V. Endoscopic retrograde cholangiography in portal cavernoma cholangiopathy—results from different studies and proposal for uniform terminology. *J Clin Exp Hepatol* 2014; **4** (suppl 1): s37–43.
- 98 Kumar M, Saraswat VA. Natural history of portal cavernoma cholangiopathy. *J Clin Exp Hepatol* 2014; **4** (suppl 1): s62–66.
- 99 Oo YH, Olliff S, Haydon G, Thorburn D. Symptomatic portal biliopathy: a single centre experience from the UK. *Eur J Gastroenterol Hepatol* 2009; **21**: 206–13.
- 100 Khare R, Sikora SS, Srikanth G, et al. Extrahepatic portal venous obstruction and obstructive jaundice: approach to management. *J Gastroenterol Hepatol* 2005; **20**: 56–61.
- 101 Costamagna G, Pandolfi M, Mutignani M, Spada C, Perri V. Long-term results of endoscopic management of postoperative bile duct strictures with increasing numbers of stents. *Gastrointest Endosc* 2001; **54**: 162–68.
- 102 Chattopadhyay S, Govindasamy M, Singla P, et al. Portal biliopathy in patients with non-cirrhotic portal hypertension: does the type of surgery affect outcome? *HPB* 2012; **14**: 441–47.
- 103 Agarwal AK, Sharma D, Singh S, Agarwal S, Girish SP. Portal biliopathy: a study of 39 surgically treated patients. *HPB* 2011; **13**: 33–39.
- 104 Acosta S. Epidemiology of mesenteric vascular disease: clinical implications. *Semin Vasc Surg* 2010; **23**: 4–8.
- 105 Elkrief L, Corcos O, Bruno O, et al. Type 2 diabetes mellitus as a risk factor for intestinal resection in patients with superior mesenteric vein thrombosis. *Liver Int* 2014; **34**: 1314–21.
- 106 Schoots IG, Koffeman GI, Legemate DA, Levi M, van Gulik TM. Systematic review of survival after acute mesenteric ischaemia according to disease aetiology. *Br J Surg* 2004; **91**: 17–27.
- 107 Wadman M, Block T, Ekberg O, Syk I, Elmstahl S, Acosta S. Impact of MDCT with intravenous contrast on the survival in patients with acute superior mesenteric artery occlusion. *Emerg Radiol* 2010; **17**: 171–78.
- 108 Nuzzo A, Joly F, Ronot M, et al. Normal lactate and unenhanced CT-scan result in delayed diagnosis of acute mesenteric ischemia. *Am J Gastroenterol* 2020; **115**: 1902–05.
- 109 Bala M, Kashuk J, Moore EE, et al. Acute mesenteric ischemia: guidelines of the World Society of Emergency Surgery. *World J Emerg Surg* 2017; **12**: 38.
- 110 Corcos O, Castier Y, Sibert A, et al. Effects of a multimodal management strategy for acute mesenteric ischemia on survival and intestinal failure. *Clin Gastroenterol Hepatol* 2013; **11**: 158–65.
- 111 Clair DG, Beach JM. Mesenteric ischemia. *N Engl J Med* 2016; **374**: 959–68.
- 112 Nuzzo A, Maggiori L, Ronot M, et al. Predictive factors of intestinal necrosis in acute mesenteric ischemia: prospective study from an intestinal stroke center. *Am J Gastroenterol* 2017; **112**: 597–605.
- 113 Nuzzo A, Maggiori L, Paugam-Burtz C, et al. Oral antibiotics reduce intestinal necrosis in acute mesenteric ischemia: a prospective cohort study. *Am J Gastroenterol* 2019; **114**: 348–51.
- 114 Gao F, Wang L, Pan J, et al. Efficacy and safety of thrombolytic therapy for portal venous system thrombosis: a systematic review and meta-analysis. *J Intern Med* 2023; **293**: 212–27.
- 115 Di Nisio M, Valeriani E, Riva N, Schulman S, Beyer-Westendorf J, Ageno W. Anticoagulant therapy for splanchnic vein thrombosis: ISTH SSC subcommittee control of anticoagulation. *J Thromb Haemost* 2020; **18**: 1562–68.
- 116 Senzolo M, Tibbals J, Cholongitas E, Triantos CK, Burroughs AK, Patch D. Transjugular intrahepatic portosystemic shunt for portal vein thrombosis with and without cavernous transformation. *Aliment Pharmacol Ther* 2006; **23**: 767–75.
- 117 Rössle M, Bettinger D, Trebicka J, et al. A prospective, multicentre study in acute non-cirrhotic, non-malignant portal vein thrombosis: comparison of medical and interventional treatment. *Aliment Pharmacol Ther* 2020; **52**: 329–39.
- 118 Benmassaoud A, AlRubaiy L, Yu D, et al. A stepwise thrombolysis regimen in the management of acute portal vein thrombosis in patients with evidence of intestinal ischaemia. *Aliment Pharmacol Ther* 2019; **50**: 1049–58.
- 119 Eugène C, Valla D, Wesenfelder L, et al. Small intestinal stricture complicating superior mesenteric vein thrombosis. A study of three cases. *Gut* 1995; **37**: 292–95.
- 120 Ribera J, Pauta M, Melgar-Lesmes P, et al. Increased nitric oxide production in lymphatic endothelial cells causes impairment of lymphatic drainage in cirrhotic rats. *Gut* 2013; **62**: 138–45.
- 121 Milazzo L, Peri AM, Lodi L, Gubertini G, Ridolfo AL, Antinori S. Intestinal lymphangiectasia and reversible high liver stiffness. *Hepatology* 2014; **60**: 759–61.
- 122 Naymagon L, Tremblay D, Zubizarreta N, Moshier E, Schiano T, Mascarenhas J. Portal vein thrombosis patients harboring JAK2V617F have poor long-term outcomes despite anticoagulation. *J Thromb Thrombolysis* 2020; **50**: 652–60.
- 123 Hollingshead M, Burke CT, Mauro MA, Weeks SM, Dixon RG, Jaques PF. Transcatheter thrombolytic therapy for acute mesenteric and portal vein thrombosis. *J Vasc Interv Radiol* 2005; **16**: 651–61.
- 124 Smalberg JH, Spaander MVMCW, Jie K-SG, et al. Risks and benefits of transcatheter thrombolytic therapy in patients with splanchnic venous thrombosis. *Thromb Haemost* 2008; **100**: 1084–88.
- 125 Cao G, Ko G-Y, Sung K-B, Yoon H-K, Gwon DI, Kim J-H. Treatment of postoperative main portal vein and superior mesenteric vein thrombosis with balloon angioplasty and/or stent placement. *Acta Radiol* 2013; **54**: 526–32.
- 126 Rosenqvist K, Eriksson L-G, Rorsman F, Sangfelt P, Nyman R. Endovascular treatment of acute and chronic portal vein thrombosis in patients with cirrhotic and non-cirrhotic liver. *Acta Radiol* 2016; **57**: 572–79.
- 127 Klinger C, Riecken B, Schmidt A, et al. Transjugular portal vein recanalization with creation of intrahepatic portosystemic shunt (PVR-TIPS) in patients with chronic non-cirrhotic, non-malignant portal vein thrombosis. *Z Gastroenterol* 2018; **56**: 221–37.
- 128 Wolter K, Decker G, Kuetting D, et al. Interventional treatment of acute portal vein thrombosis. *Rofo* 2018; **190**: 740–46.
- 129 Gerwing M, Wilms C, Heinzow H, et al. Escalating interventional recanalization therapy in non-cirrhotic, non-malignant acute portal vein thrombosis. *Eur J Gastroenterol Hepatol* 2019; **31**: 1584–91.
- 130 Mansour N, Öcal O, Gerwing M, et al. Interventional recanalization therapy in patients with non-cirrhotic, non-malignant portal vein thrombosis: comparison between transjugular versus transhepatic access. *Abdom Radiol (NY)* 2022; **47**: 1177–86.

- 131 Saito H, Sugihara F, Ueda T, et al. Efficacy of endovascular treatment for completely occlusive acute-subacute portal and mesenteric vein thrombosis with severe complications in patients without cirrhosis. *Jpn J Radiol* 2023; **41**: 541–50.
- 132 Luo J, Li M, Zhang Y, et al. Percutaneous transhepatic intrahepatic portosystemic shunt for variceal bleeding with chronic portal vein occlusion after splenectomy. *Eur Radiol* 2018; **28**: 3661–68.
- 133 Entezari P, Riaz A, Thornburg B, Salem R. Percutaneous ultrasound-guided superior and inferior mesenteric vein access for portal vein recanalization-transjugular intrahepatic portosystemic shunt: a case series. *Cardiovasc Intervent Radiol* 2021; **44**: 496–99.
- 134 Habib A, Desai K, Hickey R, et al. Portal vein recanalization-transjugularintrahepatic portosystemic shunt using the transsplenic approach to achieve transplant candidacy in patients with chronic portal vein thrombosis. *J Vasc Interv Radiol* 2015; **26**: 499–506.
- 135 Semiz-Oysu A, Keussen I, Cwikiel W. Interventional radiological management of prehepatic obstruction of [corrected] the splanchnic venous system. *Cardiovasc Intervent Radiol* 2007; **30**: 688–95.
- 136 Woodrum DA, Bjarnason H, Andrews JC. Portal vein venoplasty and stent placement in the nontransplant population. *J Vasc Interv Radiol* 2009; **20**: 593–99.
- 137 Liu J, Zhou C, Shi Q, et al. Exploration of interventional therapy strategy for portal vein occlusion: a case series study. *Eur J Gastroenterol Hepatol* 2020; **32**: 507–16.
- 138 Kobe A, Puipe G, Müllhaupt B, Pfammatter T. Recanalization of chronic noncirrhotic, nonmalignant splanchnic thromboses is feasible: a transsplenic assisted patient-tailored approach. *J Vasc Interv Radiol* 2021; **32**: 1377–85.
- 139 Smith ML, Wade JB, Wolstenholme J, Bajaj JS. Gut microbiome-brain-cirrhosis axis. *Hepatology* 2023; published online March 6. <https://doi.org/10.1097/HEP.0000000000000344>.
- 140 Carol M, Pérez-Guasc M, Solà E, et al. Stigmatization is common in patients with non-alcoholic fatty liver disease and correlates with quality of life. *PLoS One* 2022; **17**: e0265153.
- 141 Schomerus G, Leonhard A, Manthey J, et al. The stigma of alcohol-related liver disease and its impact on healthcare. *J Hepatol* 2022; **77**: 516–24.
- 142 Shiha G, Korenjak M, Casanovas T, et al. MAFLD 2022: an ELPA/ALPA/EASO-ECPO joint statement on disease stigma. *J Hepatol* 2022; **77**: 1717–19.
- 143 Tu T. Stigma: a major barrier to hepatitis B elimination. *Nat Rev Gastroenterol Hepatol* 2022; **19**: 622.
- 144 Gairing SJ, Galle PR, Schattenberg JM, Kostev K, Labenz C. Portal vein thrombosis is associated with an increased incidence of depression and anxiety disorders. *J Clin Med* 2021; **10**: 5689.
- 145 Battaglioli T, Martinelli I. Hormone therapy and thromboembolic disease. *Curr Opin Hematol* 2007; **14**: 488–93.
- 146 Marik PE, Plante LA. Venous thromboembolic disease and pregnancy. *N Engl J Med* 2008; **359**: 2025–33.
- 147 Pabinger I, Grafenhofer H. Thrombosis during pregnancy: risk factors, diagnosis and treatment. *Pathophysiol Haemost Thromb* 2002; **32**: 322–24.
- 148 Bates SM, Greer IA, Middeldorp S, Veenstra DL, Prabulos A-M, Vandvik PO. VTE, thrombophilia, antithrombotic therapy, and pregnancy: antithrombotic therapy and prevention of thrombosis, 9th ed: American College of Chest Physicians evidence-based clinical practice guidelines. *Chest* 2012; **141** (suppl): e691S–e736S.
- 149 Wieggers H, Hamulyák EN, Damhuis SE, et al. Pregnancy outcomes in women with Budd–Chiari syndrome or portal vein thrombosis—a multicentre retrospective cohort study. *BJOG* 2022; **129**: 608–17.
- 150 Janssen HL, Wijnhoud A, Haagsma EB, et al. Extrahepatic portal vein thrombosis: aetiology and determinants of survival. *Gut* 2001; **49**: 720–24.
- 151 Mandal D, Dattaray C, Sarkar R, Mandal S, Choudhary A, Maity TK. Is pregnancy safe with extrahepatic portal vein obstruction? An analysis. *Singapore Med J* 2012; **53**: 676–80.
- 152 Shukla A, Sadalage A, Gupta D, et al. Pregnancy outcomes in women with Budd–Chiari syndrome before onset of symptoms and after treatment. *Liver Int* 2018; **38**: 754–59.
- 153 Ramani N, Kawi K, Karad A, et al. Gonadal dysfunction in male patients with Budd–Chiari syndrome and its reversibility with treatment. *Hepatol Int* 2022; **16**: 640–48.
- 154 Hoekstra J, Seijo S, Rautou PE, et al. Pregnancy in women with portal vein thrombosis: results of a multicentric European study on maternal and fetal management and outcome. *J Hepatol* 2012; **57**: 1214–19.
- 155 Aggarwal N, Chopra S, Raveendran A, Suri V, Dhiman RK, Chawla YK. Extra hepatic portal vein obstruction and pregnancy outcome: largest reported experience. *J Obstet Gynaecol Res* 2011; **37**: 575–80.
- 156 Shukla A, Singh A, Saxena A, et al. Navigating portal hypertension: unlocking safe passage to healthy pregnancy in EHPVO. *Liver Int* 2024; **44**: 454–59.
- 157 Payancé A, Ceccaldi PF, De Raucourt E, et al. Pregnancy and vascular liver diseases: vascular liver diseases: position papers from the francophone network for vascular liver diseases, the French Association for the Study of the Liver (AFL), and ERN-rare liver. *Clin Res Hepatol Gastroenterol* 2020; **44**: 433–37.
- 158 Sarin SK, Bansal A, Sasan S, Nigam A. Portal-vein obstruction in children leads to growth retardation. *Hepatology* 1992; **15**: 229–33.
- 159 Bersani I, Piersigilli F, Iacona G, et al. Incidence of umbilical vein catheter-associated thrombosis of the portal system: a systematic review and meta-analysis. *World J Hepatol* 2021; **13**: 1802–15.
- 160 Williams S, Chan AKC. Neonatal portal vein thrombosis: diagnosis and management. *Semin Fetal Neonatal Med* 2011; **16**: 329–39.
- 161 Koo KSH, Lamar DL, Shaw DWW, Monroe EJ, Shivaram GM. Catheter-directed thrombolysis for portal vein thrombosis in children: a case series. *J Vasc Interv Radiol* 2018; **29**: 1578–83.
- 162 Superina RA, de Ville de Goyet J. Pre-emptive Meso-Rex bypass for children with idiopathic prehepatic portal hypertension: trick or treat? *J Pediatr Gastroenterol Nutr* 2014; **58**: e41.
- 163 Mack CL, Zelko FA, Lokar J, et al. Surgically restoring portal blood flow to the liver in children with primary extrahepatic portal vein thrombosis improves fluid neurocognitive ability. *Pediatrics* 2006; **117**: e405–12.
- 164 Bertocchini A, Falappa P, Grimaldi C, Bolla G, Monti L, de Ville de Goyet J. Intrahepatic portal venous systems in children with noncirrhotic prehepatic portal hypertension: anatomy and clinical relevance. *J Pediatr Surg* 2014; **49**: 1268–75.
- 165 Superina RA, Alonso EM. Medical and surgical management of portal hypertension in children. *Curr Treat Options Gastroenterol* 2006; **9**: 432–43.
- 166 Chiu B, Superina RA. Encephalopathy caused by a splenorenal shunt can be reversed by performing a mesenteric-to-left portal vein bypass. *J Pediatr Surg* 2006; **41**: 1177–79.
- 167 Pan J, Wang L, Gao F, et al. Epidemiology of portal vein thrombosis in liver cirrhosis: a systematic review and meta-analysis. *Eur J Intern Med* 2022; **104**: 21–32.
- 168 Bert J, Geerts A, Vanlander A, et al. Up to 50% of portal vein thrombosis remains undiagnosed until liver transplantation. *Clin Transplant* 2020; **34**: e14107.
- 169 Nery F, Chevret S, Condat B, et al. Causes and consequences of portal vein thrombosis in 1243 patients with cirrhosis: results of a longitudinal study. *Hepatology* 2015; **61**: 660–67.
- 170 Zocco MA, Di Stasio E, De Cristofaro R, et al. Thrombotic risk factors in patients with liver cirrhosis: correlation with MELD scoring system and portal vein thrombosis development. *J Hepatol* 2009; **51**: 682–89.
- 171 Nery F, Correia S, Macedo C, et al. Nonselective beta-blockers and the risk of portal vein thrombosis in patients with cirrhosis: results of a prospective longitudinal study. *Aliment Pharmacol Ther* 2019; **49**: 582–88.
- 172 Xu X, Guo X, De Stefano V, et al. Nonselective beta-blockers and development of portal vein thrombosis in liver cirrhosis: a systematic review and meta-analysis. *Hepatol Int* 2019; **13**: 468–81.
- 173 Xing Y, Tian Z, Jiang Y, et al. A practical nomogram based on systemic inflammatory markers for predicting portal vein thrombosis in patients with liver cirrhosis. *Ann Med* 2022; **54**: 302–09.
- 174 Nery F, Carneiro P, Correia S, et al. Systemic inflammation as a risk factor for portal vein thrombosis in cirrhosis: a prospective longitudinal study. *Eur J Gastroenterol Hepatol* 2021; **33** (suppl 1): e108–13.
- 175 Huang X, Fan X, Zhang R, Jiang S, Yang K, Chen S. Systemic inflammation and portal vein thrombosis in cirrhotic patients with gastroesophageal varices. *Eur J Gastroenterol Hepatol* 2020; **32**: 401–05.

- 176 Qi X, Guo X, Yoshida EM, et al. Transient portal vein thrombosis in liver cirrhosis. *BMC Med* 2018; **16**: 83.
- 177 Francoz C, Belghiti J, Vilgrain V, et al. Splanchnic vein thrombosis in candidates for liver transplantation: usefulness of screening and anticoagulation. *Gut* 2005; **54**: 691–97.
- 178 Molinari M, Fernandez-Carrillo C, Dai D, et al. Portal vein thrombosis and renal dysfunction: a national comparative study of liver transplant recipients for NAFLD versus alcoholic cirrhosis. *Transpl Int* 2021; **34**: 1105–22.
- 179 Qi X, Ren W, De Stefano V, Fan D. Associations of coagulation factor V Leiden and prothrombin G20210A mutations with Budd–Chiari syndrome and portal vein thrombosis: a systematic review and meta-analysis. *Clin Gastroenterol Hepatol* 2014; **12**: 1801–12.
- 180 Scheiner B, Northup PG, Gruber AB, et al. The impact of ABO blood type on the prevalence of portal vein thrombosis in patients with advanced chronic liver disease. *Liver Int* 2020; **40**: 1415–26.
- 181 Ollivier-Hourmand I, Repesse Y, Nahon P, et al. ABO blood group does not influence Child-Pugh A cirrhosis outcome: an observational study from CIRRAL and ANRS CO12 CIRVIR cohorts. *Liver Int* 2022; **42**: 1386–400.
- 182 Fortea JI, Carrera IG, Puente Á, et al. Portal thrombosis in cirrhosis: role of thrombophilic disorders. *J Clin Med* 2020; **9**: 2822.
- 183 Semmler G, Lens S, Meyer EL, et al. Non-invasive tests for clinically significant portal hypertension after HCV cure. *J Hepatol* 2022; **77**: 1573–85.
- 184 Bradley C, Scott RA, Cox E, et al. Short-term changes observed in multiparametric liver MRI following therapy with direct-acting antivirals in chronic hepatitis C virus patients. *Eur Radiol* 2019; **29**: 3100–07.
- 185 Faheem HA, Abdulmegeed NA, Hussein HA, Elmoursi AA, Elnaggar HTMY, Ghait RS. Impact of sustained virologic response in regression of portal hypertension in Egyptian patients with hepatitis C virus-associated cirrhosis and portal hypertension. *Egypt Liver J* 2022; **12**: 27.
- 186 Tripodi A, D'Ambrosio R, Padovan L, et al. Evaluation of coagulation during treatment with directly acting antivirals in patients with hepatitis C virus related cirrhosis. *Liver Int* 2017; **37**: 1295–303.
- 187 Russo FP, Zanetto A, Campello E, et al. Reversal of hypercoagulability in patients with HCV-related cirrhosis after treatment with direct-acting antivirals. *Liver Int* 2018; **38**: 2210–18.
- 188 Muñoz-Hernández R, Ampuero J, Millán R, et al. Hepatitis C virus clearance by direct-acting antiviral agents improves endothelial dysfunction and subclinical atherosclerosis: HEPICAR study. *Clin Transl Gastroenterol* 2020; **11**: e00203.
- 189 Di Minno MND, Ambrosino P, Buonomo AR, et al. Direct-acting antivirals improve endothelial function in patients with chronic hepatitis: a prospective cohort study. *Intern Emerg Med* 2020; **15**: 263–71.
- 190 Álvarez B, Restrepo C, García M, et al. Liver stiffness hinders normalization of systemic inflammation and endothelial activation after hepatitis C virus (HCV) eradication in HIV/HCV coinfecting patients. *Vaccines (Basel)* 2020; **8**: 323.
- 191 Caballero-Marcos A, Romero-Cristóbal M, Puerto M, et al. HCV eradication in recurrent hepatitis C after liver transplantation normalizes enhanced endothelial activation. *Transpl Int* 2021; **34**: 2214–25.
- 192 Bauer D, Kozbial K, Schwabl P, et al. Angiopoietin 2 levels decrease after HCV-cure and reflect the evolution of portal hypertension. *Dig Liver Dis* 2022; **54**: 1222–29.
- 193 Mandorfer M, Turon F, Lens S, et al. Risk of non-tumoural portal vein thrombosis in patients with HCV-induced cirrhosis after sustained virological response. *Liver Int* 2021; **41**: 2954–64.
- 194 Kondili LA, Zanetto A, Quaranta MG, et al. Predicting de-novo portal vein thrombosis after HCV eradication: a long-term competing risk analysis in the ongoing PITER cohort. *United European Gastroenterol J* 2024; **12**: 352–63.
- 195 Gao Z, Zhao J, Liu X, Li S, Wang M, Gao Y. Portal vein thrombosis associated with high 14-day and 6-week rebleeding in patients after oesophageal variceal band ligation: a retrospective, multicentre, nested case-control study. *Hepatol Int* 2021; **15**: 1183–95.
- 196 Augustin S, Altamirano J, González A, et al. Effectiveness of combined pharmacologic and ligation therapy in high-risk patients with acute esophageal variceal bleeding. *Am J Gastroenterol* 2011; **106**: 1787–95.
- 197 Dell'Era A, Iannuzzi F, Fabris FM, et al. Impact of portal vein thrombosis on the efficacy of endoscopic variceal band ligation. *Dig Liver Dis* 2014; **46**: 152–56.
- 198 Lv Y, Qi X, He C, et al. Covered TIPS versus endoscopic band ligation plus propranolol for the prevention of variceal rebleeding in cirrhotic patients with portal vein thrombosis: a randomised controlled trial. *Gut* 2018; **67**: 2156–68.
- 199 Nicoară-Farcău O, Han G, Rudler M, et al. Effects of early placement of transjugular portosystemic shunts in patients with high-risk acute variceal bleeding: a meta-analysis of individual patient data. *Gastroenterology* 2021; **160**: 193–205.
- 200 Loffredo L, Pastori D, Farcomeni A, Violi F. Effects of anticoagulants in patients with cirrhosis and portal vein thrombosis: a systematic review and meta-analysis. *Gastroenterology* 2017; **153**: 480–87.
- 201 Cerini F, Gonzalez JM, Torres F, et al. Impact of anticoagulation on upper-gastrointestinal bleeding in cirrhosis. A retrospective multicenter study. *Hepatology* 2015; **62**: 575–83.
- 202 Xu S, Guo X, Xu X, et al. Natural history and predictors associated with the evolution of portal venous system thrombosis in liver cirrhosis. *Eur J Gastroenterol Hepatol* 2021; **33** (suppl 1): e423–30.
- 203 Senzolo M, Sartori T, Rossetto V, et al. Prospective evaluation of anticoagulation and transjugular intrahepatic portosystemic shunt for the management of portal vein thrombosis in cirrhosis. *Liver Int* 2012; **32**: 919–27.
- 204 Villa E, Cammà C, Marietta M, Luongo M, Critelli R, Colopi S, et al. Enoxaparin prevents portal vein thrombosis and liver decompensation in patients with advanced cirrhosis. *Gastroenterology* 2012; **143**: 1253–60.
- 205 Sanchez AP, Turon F, Martinez J, et al. Rivaroxaban improves survival and decompensation in cirrhotic patients with moderate liver dysfunction. Double-blind, placebo-controlled trial. *J Hepatol* 2023; **78**: S2–3.
- 206 Serper M, Weinberg EM, Cohen JB, Reese PP, Taddei TH, Kaplan DE. Mortality and hepatic decompensation in patients with cirrhosis and atrial fibrillation treated with anticoagulation. *Hepatology* 2021; **73**: 219–32.
- 207 Guerrero A, Campo LD, Piscaglia F, et al. Anticoagulation improves survival in patients with cirrhosis and portal vein thrombosis: the IMPORTANT competing-risk meta-analysis. *J Hepatol* 2023; **79**: 69–78.
- 208 Valeriani E, Di Nisio M, Riva N, et al. Anticoagulant treatment for splanchnic vein thrombosis in liver cirrhosis: a systematic review and meta-analysis. *Thromb Haemost* 2021; **121**: 867–76.
- 209 Wang L, Guo X, Xu X, et al. Anticoagulation favors thrombus recanalization and survival in patients with liver cirrhosis and portal vein thrombosis: results of a meta-analysis. *Adv Ther* 2021; **38**: 495–520.
- 210 Tripodi A, Salerno F, Chantarangkul V, et al. Evidence of normal thrombin generation in cirrhosis despite abnormal conventional coagulation tests. *Hepatology* 2005; **41**: 553–58.
- 211 Anstee QM, Goldin RD, Wright M, Martinelli A, Cox R, Thursz MR. Coagulation status modulates murine hepatic fibrogenesis: implications for the development of novel therapies. *J Thromb Haemost* 2008; **6**: 1336–43.
- 212 Simonetto DA, Yang HY, Yin M, et al. Chronic passive venous congestion drives hepatic fibrogenesis via sinusoidal thrombosis and mechanical forces. *Hepatology* 2015; **61**: 648–59.
- 213 Cerini F, Vilaseca M, Lafoz E, et al. Enoxaparin reduces hepatic vascular resistance and portal pressure in cirrhotic rats. *J Hepatol* 2016; **64**: 834–42.
- 214 Vilaseca M, García-Calderó H, Lafoz E, et al. The anticoagulant rivaroxaban lowers portal hypertension in cirrhotic rats mainly by deactivating hepatic stellate cells. *Hepatology* 2017; **65**: 2031–44.
- 215 Northup PG, Garcia-Pagan JC, Garcia-Tsao G, et al. Vascular liver disorders, portal vein thrombosis, and procedural bleeding in patients with liver disease: 2020 practice guidance by the American Association for the Study of Liver Diseases. *Hepatology* 2021; **73**: 366–413.
- 216 Senzolo M, Rodriguez-Castro KI, Rossetto V, et al. Increased anticoagulant response to low-molecular-weight heparin in plasma from patients with advanced cirrhosis. *J Thromb Haemost* 2012; **10**: 1823–29.

- 217 Senzolo M, Piano S, Shalaby S, et al. Comparison of fondaparinux and low-molecular-weight heparin in the treatment of portal vein thrombosis in cirrhosis. *Am J Med* 2021; **134**: 1278–85.
- 218 Delgado MG, Seijo S, Yepes I, et al. Efficacy and safety of anticoagulation on patients with cirrhosis and portal vein thrombosis. *Clin Gastroenterol Hepatol* 2012; **10**: 776–83.
- 219 Dong S, Qi H, Li Y, et al. A systematic review and meta-analysis of anticoagulation therapy for portal vein thrombosis in patients with cirrhosis: to treat or not to treat? *Hepatol Int* 2021; **15**: 1356–75.
- 220 Gupta S, Hidalgo J, Singh B, et al. Usage of direct acting oral anticoagulants in cirrhotic and non-cirrhotic portal vein thrombosis: a systematic review. *Cureus* 2021; **13**: e16922.
- 221 Koh JH, Liew ZH, Ng GK, et al. Efficacy and safety of direct oral anticoagulants versus vitamin K antagonist for portal vein thrombosis in cirrhosis: a systematic review and meta-analysis. *Dig Liver Dis* 2022; **54**: 56–62.
- 222 Ng CH, Tan DJH, Nistala KRY, et al. A network meta-analysis of direct oral anticoagulants for portal vein thrombosis in cirrhosis. *Hepatol Int* 2021; **15**: 1196–206.
- 223 De Gottardi A, Trebicka J, Klinger C, et al. Antithrombotic treatment with direct-acting oral anticoagulants in patients with splanchnic vein thrombosis and cirrhosis. *Liver Int* 2017; **37**: 694–99.
- 224 Lisman T, Bernal W, Adelmeijer J, Kamphuisen P-W, Bos S, Porte RJ. Clinically relevant increases in the international normalized ratio and model of end-stage liver disease score by therapeutic doses of direct oral anticoagulants in patients with cirrhosis. *Res Pract Thromb Haemost* 2023; **7**: 100052.
- 225 Semmler G, Pomej K, Bauer DJM, et al. Safety of direct oral anticoagulants in patients with advanced liver disease. *Liver Int* 2021; **41**: 2159–70.
- 226 Violi F, Vestri A, Menichelli D, Di Rocco A, Pastori D, Pignatelli P. Direct oral anticoagulants in patients with atrial fibrillation and advanced liver disease: an exploratory meta-analysis. *Hepatol Commun* 2020; **4**: 1034–40.
- 227 Nisly SA, Mihm AE, Gillette C, Davis KA, Tillett J. Safety of direct oral anticoagulants in patients with mild to moderate cirrhosis: a systematic review and meta-analysis. *J Thromb Thrombolysis* 2021; **52**: 817–27.
- 228 Intagliata NM, Davitkov P, Allen AM, Falck-Ytter YT, Stine JG. AGA technical review on coagulation in cirrhosis. *Gastroenterology* 2021; **161**: 1630–56.
- 229 Li Z, Xu W, Wang L, et al. Risk of bleeding in liver cirrhosis receiving direct oral anticoagulants: a systematic review and meta-analysis. *Thromb Haemost* 2023; **123**: 1072–88.
- 230 Williams C, Stewart E, Conzen KD, Wolf S, Tran TT. Dabigatran reversal with idarucizumab in 2 patients with portal vein thrombosis undergoing orthotopic liver transplantation. *Semin Cardiothorac Vasc Anesth* 2021; **25**: 200–07.
- 231 Intagliata NM, Maitland H, Pellitier S, Caldwell SH. Reversal of direct oral anticoagulants for liver transplantation in cirrhosis: a step forward. *Liver Transpl* 2017; **23**: 396–97.
- 232 Amitrano L, Guardascione MA, Menchise A, et al. Safety and efficacy of anticoagulation therapy with low molecular weight heparin for portal vein thrombosis in patients with liver cirrhosis. *J Clin Gastroenterol* 2010; **44**: 448–51.
- 233 Rodríguez-Castro KI, Senzolo M, Sartori MT. Optimal length of anticoagulant therapy in cirrhotic patients with portal vein thrombosis. *Clin Gastroenterol Hepatol* 2012; **10**: 820–21.
- 234 Ferral H, Gamboa P, Postoak DW, et al. Survival after elective transjugular intrahepatic portosystemic shunt creation: prediction with model for end-stage liver disease score. *Radiology* 2004; **231**: 231–36.
- 235 Horhat A, Bureau C, Thabut D, Rudler M. Transjugular intrahepatic portosystemic shunt in patients with cirrhosis: indications and posttransjugular intrahepatic portosystemic shunt complications in 2020. *United European Gastroenterol J* 2021; **9**: 203–08.
- 236 Thornburg B, Desai K, Hickey R, et al. Pretransplantation portal vein recanalization and transjugular intrahepatic portosystemic shunt creation for chronic portal vein thrombosis: final analysis of a 61-patient cohort. *J Vasc Interv Radiol* 2017; **28**: 1714–21.
- 237 Rodrigues SG, Sixt S, Abalde JG, et al. Systematic review with meta-analysis: portal vein recanalisation and transjugular intrahepatic portosystemic shunt for portal vein thrombosis. *Aliment Pharmacol Ther* 2019; **49**: 20–30.
- 238 Wang Z, Jiang M-S, Zhang H-L, et al. Is post-TIPS anticoagulation therapy necessary in patients with cirrhosis and portal vein thrombosis? A randomized controlled trial. *Radiology* 2016; **279**: 943–51.
- 239 Luca A, Miraglia R, Caruso S, et al. Short- and long-term effects of the transjugular intrahepatic portosystemic shunt on portal vein thrombosis in patients with cirrhosis. *Gut* 2011; **60**: 846–52.
- 240 Sherman CB, Behr S, Dodge JL, Roberts JP, Yao FY, Mehta N. Distinguishing tumor from bland portal vein thrombus in liver transplant candidates with hepatocellular carcinoma: the A-VENA criteria. *Liver Transpl* 2019; **25**: 207–16.
- 241 Rodríguez-Castro KI, Porte RJ, Nadal E, Germani G, Burra P, Senzolo M. Management of nonneoplastic portal vein thrombosis in the setting of liver transplantation: a systematic review. *Transplantation* 2012; **94**: 1145–53.
- 242 Davidson BR, Gibson M, Dick R, Burroughs A, Rolles K. Incidence, risk factors, management, and outcome of portal vein abnormalities at orthotopic liver transplantation. *Transplantation* 1994; **57**: 1174–77.
- 243 Ravaoli M, Zanello M, Grazi GL, et al. Portal vein thrombosis and liver transplantation: evolution during 10 years of experience at the University of Bologna. *Ann Surg* 2011; **253**: 378–84.
- 244 Faccia M, Santopao F, Gasbarrini A, Pompili M, Zocco MA, Ponziani FR. Risk factors for portal vein thrombosis or venous thromboembolism in a large cohort of hospitalized cirrhotic patients. *Intern Emerg Med* 2022; **17**: 1327–34.
- 245 Zanetto A, Senzolo M, Vitale A, et al. Thromboelastometry hypercoagulable profiles and portal vein thrombosis in cirrhotic patients with hepatocellular carcinoma. *Dig Liver Dis* 2017; **49**: 440–45.
- 246 Mahmoudi TM, Marquez V, Kayal A, Carvalho R, Weiss AA. HCC complicated by PVT: outcome and the role of anticoagulation therapy. *Can Liver J* 2019; **2**: 121–26.
- 247 Grasso M, Vitale A, Pizzirani E, et al. Analysis of clinical course of portal vein thrombosis in cirrhosis with hepatocellular carcinoma. *Dig Liver Dis* 2021; **53**: S43.
- 248 Zanetto A, Campello E, Pelizzaro F, et al. Haemostatic alterations in patients with cirrhosis and hepatocellular carcinoma: laboratory evidence and clinical implications. *Liver Int* 2022; **42**: 1229–40.
- 249 Senzolo M, Shalaby S, Grasso M, et al. Role of non-neoplastic portal vein thrombosis in the natural history of patients with cirrhosis and first diagnosis of hepatocellular carcinoma. *Hepatology* 2024; **79**: 355–67.
- 250 Falanga A, Brenner B, Khorana AA, Francis CW. Thrombotic complications in patients with cancer: advances in pathogenesis, prevention, and treatment—A report from ICTHIC 2021. *Res Pract Thromb Haemost* 2022; **6**: e12744.
- 251 Haouala A, Widmer N, Duchosal MA, Montemurro M, Buclin T, Decosterd LA. Drug interactions with the tyrosine kinase inhibitors imatinib, dasatinib, and nilotinib. *Blood* 2011; **117**: e75–87.
- 252 Lafaie L, Hodin S, Saïb S, Bin V, Bertoletti L, Delavenne X. Tyrosine kinase inhibitors and direct oral anticoagulants: in vitro evaluation of drug-drug interaction mediated by P-glycoprotein. *Fundam Clin Pharmacol* 2022; **36**: 860–68.
- 253 Patel SH, George TL, Wang T-F, et al. Increased bleeding risk associated with concurrent vascular endothelial growth factor receptor tyrosine kinase inhibitors and low-molecular-weight heparin. *Cancer* 2021; **127**: 938–45.
- 254 Kelly DM, Shiba H, Nakagawa S, et al. Hepatic blood flow plays an important role in ischemia-reperfusion injury. *Liver Transpl* 2011; **17**: 1448–56.
- 255 Bhangui P, Lim C, Levesque E, et al. Novel classification of non-malignant portal vein thrombosis: a guide to surgical decision-making during liver transplantation. *J Hepatol* 2019; **71**: 1038–50.
- 256 Yerdel MA, Gunson B, Mirza D, et al. Portal vein thrombosis in adults undergoing liver transplantation: risk factors, screening, management, and outcome. *Transplantation* 2000; **69**: 1873–81.
- 257 Azoulay D, Quintini C, Rayar M, et al. Renoportal anastomosis during liver transplantation in patients with portal vein thrombosis: first long-term results from a multicenter study. *Ann Surg* 2022; **276**: e825–33.

- 258 Ghabril M, Agarwal S, Lacerda M, Chalasani N, Kwo P, Tector AJ. Portal vein thrombosis is a risk factor for poor early outcomes after liver transplantation: analysis of risk factors and outcomes for portal vein thrombosis in waitlisted patients. *Transplantation* 2016; **100**: 126–33.
- 259 Sanchez-Ocaña R, Tejedor-Tejada J, Cimavilla-Roman M, et al. Utility of oral anticoagulants as prophylaxis of recurrent portal thrombosis after liver transplantation. *Transplant Proc* 2019; **51**: 83–86.
- 260 Bos I, Blondeau M, Wouters D, et al. Therapeutic anticoagulation after liver transplantation is not useful among patients with pre-transplant Yerdel-grade I/II portal vein thrombosis: a two-center retrospective study. *J Thromb Haemost* 2021; **19**: 2760–71.
- 261 Hepatobiliary Disease Study Group, Chinese Society of Gastroenterology, Chinese Medical Association. Consensus for management of portal vein thrombosis in liver cirrhosis (2020, Shanghai). *J Dig Dis* 2021; **22**: 176–86.
- 262 Bauer J, Johnson S, Durham J, et al. The role of TIPS for portal vein patency in liver transplant patients with portal vein thrombosis. *Liver Transpl* 2006; **12**: 1544–51.
- 263 Fink MA, Mayer VL, Schneider T, et al. CT angiography clot burden score from data mining of structured reports for pulmonary embolism. *Radiology* 2022; **302**: 175–84.
- 264 Ma J, Yan Z, Luo J, Liu Q, Wang J, Qiu S. Rational classification of portal vein thrombosis and its clinical significance. *PLoS One* 2014; **9**: e112501.
- 265 Onda S, Furukawa K, Shirai Y, et al. New classification-oriented treatment strategy for portal vein thrombosis after hepatectomy. *Ann Gastroenterol Surg* 2020; **4**: 701–09.
- 266 Ikai I, Kudo M, Arai S, et al. Report of the 18th follow-up survey of primary liver cancer in Japan. *Hepatol Res* 2010; **40**: 1043–59.
- 267 Plaforet V, Moga L, Elkrief L, Rautou PE, Ronot M. Inter-reader reliability for the assessment of portal vein thrombosis. *Insights Imaging* 2024; **15** (suppl 1): 123.
- 268 Eisenhauer EA, Therasse P, Bogaerts J, et al. New response evaluation criteria in solid tumours: revised RECIST guideline (version 1.1). *Eur J Cancer* 2009; **45**: 228–47.
- 269 Luca A, Caruso S, Milazzo M, et al. Natural course of extrahepatic non-malignant partial portal vein thrombosis in patients with cirrhosis. *Radiology* 2012; **265**: 124–32.
- 270 Suda T, Takatori H, Hayashi T, et al. Investigation of thrombosis volume, anticoagulants, and recurrence factors in portal vein thrombosis with cirrhosis. *Life* 2020; **10**: 177.
- 271 Condat B, Pessione F, Helene Denninger M, Hillaire S, Valla D. Recent portal or mesenteric venous thrombosis: increased recognition and frequent recanalization on anticoagulant therapy. *Hepatology* 2000; **32**: 466–70.
- 272 Amitrano L, Guardascione MA, Scaglione M, et al. Prognostic factors in non-cirrhotic patients with splanchnic vein thromboses. *Am J Gastroenterol* 2007; **102**: 2464–70.
- 273 Condat B, Pessione F, Hillaire S, et al. Current outcome of portal vein thrombosis in adults: risk and benefit of anticoagulant therapy. *Gastroenterology* 2001; **120**: 490–97.